

Increased Telomere Length and Improvements in Dysautonomia, Quality of Life, and Neck and Back Pain Following Correction of Sagittal Cervical Alignment Using Chiropractic BioPhysics® Technique: a Case Study

Fedorchuk C*, Lightstone DF, McCoy M and Harrison DE

425 Peachtree Parkway, Suite 315, Cumming, GA 30041, United States

Abstract

Objective: To present a prospective case study on the increase of telomere length, improvement in nocturnal polyuria, neck and mid-back pain, autonomic nervous system adaptability, and health-related quality of life following correction of the sagittal cervico-thoracic spinal alignment and posture using chiropractic biophysics® (CBP®) technique.

Clinical features: A 35-year-old white female elementary school teacher presented with chronic neck and mid-back pain for 5 years following a motor vehicle collision as well as nocturnal polyuria. Examination and radiography revealed forward head posture and loss of cervical lordosis consistent with vertebral subluxation. Patient telomere length was derived from nucleated white blood cells obtained from a blood test. Quality of life measures were determined by the Short-Form 36 health survey and heart rate variability was measured.

Intervention and outcome: The patient received CBP® spinal care including Mirror Image® corrective spinal exercises, adjustments, and traction. Full spine and drop table adjustments were administered. After 36 visits, she reported improvement in her nocturnal polyuria, neck and mid-back pain, and quality of life. Cervical x-rays showed correction of cervical lordosis and forward head posture. A blood test showed significant improvement in patient telomere length and heart rate variability improved from a health risk to within normal limits.

Conclusion: Our case suggests that correction of cervical lordosis and forward head postures by CBP® Mirror Image® methods improved the sagittal spinal alignment and posture and was temporally associated with lengthened telomeres, improved nocturnal polyuria, neck and mid-back pain, quality of life, and autonomic nervous system adaptability.

Keywords: Chiropractic BioPhysics®; CBP®; Adjustments; Traction; Cervical spine posture; Lordosis; Telomere length; Quality of life; Nocturnal polyuria; Vertebral subluxation

Abbreviations: CBP®: Chiropractic BioPhysics®; TL: Telomere Length; NP: Neck Pain; MVC: Motor Vehicle Collision; NRS: Numeric Rating Scale; HRV: Heart Rate Variability; AAI: Autonomic Activity Index; ABI: Autonomic Balance Index; S: Sympathetic Nervous System; P: Parasympathetic Nervous System; SF-36: Short Form 36-Question Health Survey; QOL: Quality of Life; +TzH: Positive Translation of the Head in The Z-Axis; AP: Anterior-to-Posterior; NLC: Neutral Lateral Cervical; EMR: Electronic Medical Record; WNL: Within Normal Limits; Tz C2-C7: Translation of the posterior superior body corner of C2 with respect to a vertical line originating at the posterior inferior body corner of C7 in the z-axis as seen in the sagittal view of the cervical spine; APL: Atlas Plane Line; ARA C2-C7: Absolute rotational angle of the cervical region measuring the angle between the lines tangent to the posterior vertebral body margins of the C2 and C7 vertebrae in the sagittal view; CNS: Central Nervous System; n: Number of participants; RRA: Relative Rotational Angle; ARA: Absolute Rotational Angle; Tz: Translation in the z axis; PF: Physical Functioning; PRL: Physical Role Limitations; ERL: Emotional Role Limitations; EWB: Emotional Well-Being; V: Vitality; SF: Social Functioning; P!: Pain; GH: General Health; ΔHS: Change in Health Status

Introduction

Human telomere length (TL) is affected by genetic and environmental factors [1]. TL is longest at birth and decreases with advancing age [2]. As such, telomere length is considered a biomarker of biological aging [2,3]. As telomeres shorten, cells can lose their ability to undergo cellular sequencing (replication and division) and

may undergo apoptosis (cell death) [4]. In various cross-sectional studies, observations of shortened TL are associated with metabolic and inflammatory diseases [3,5], pulmonary diseases [3,6], cardiovascular events and diseases [3,7-10], psychological and stress disorders [3], neurodegenerative diseases [3], cancer [3,11], chronic and serious illnesses [3], and mortality [3,10]. Additionally, TL is associated with lifestyle choices such as diet, tobacco and alcohol use [12], physical activity, and sleep [3]. Fewer studies have focused on the dynamic change and regulation of TL by implementing exercise programs [13,14], vitamin supplements [15], diet [16], meditation [17], and genetic engineering [18]. Interest in telomere lengthening or length maintenance is due to the notion that this will serve to slow down or cease a person's biological clock providing youthfulness and health longevity [10]. It seems that implementation of healthy interventions or reduction of unhealthy stressors will have a beneficial effect on TL. The effects of chiropractic care on TL have not been studied.

***Corresponding author:** Dr. Curtis Fedorchuk, 425 Peachtree Parkway, Suite 315, Cumming, GA 30041, United States, Tel: 7705732777; Fax: 7708881176; E-mail: cfedorchuk@comcast.net

Received May 23, 2017; Accepted June 09, 2017; Published June 13, 2017

Citation: Fedorchuk C, Lightstone DF, McCoy M, Harrison DE (2017) Increased Telomere Length and Improvements in Dysautonomia, Quality of Life, and Neck and Back Pain Following Correction of Sagittal Cervical Alignment Using Chiropractic BioPhysics® Technique: a Case Study. J Mol Genet Med 11: 269 doi:10.4172/1747-0862.1000269

Copyright: © 2017 Fedorchuk C, et al. This is an open-access article distributed under the terms of the Creative Commons Attribution License, which permits unrestricted use, distribution, and reproduction in any medium, provided the original author and source are credited

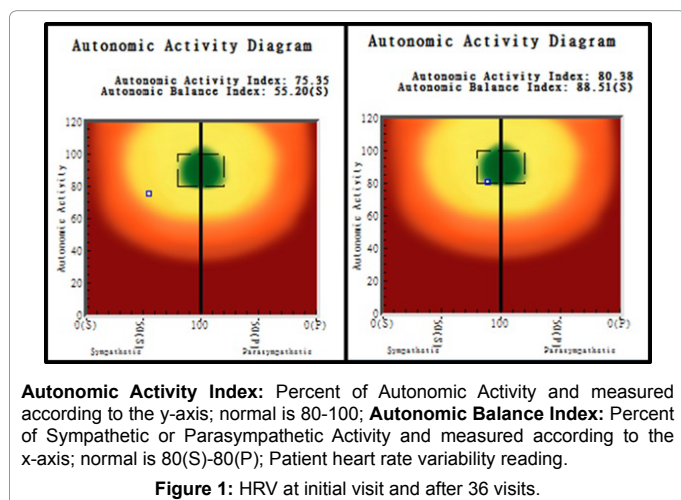
Neck pain (NP) and back pain are common presentations in chiropractic practices and chiropractic management thereof varies between practitioners [19]. Cervical spine misalignment resulting in vertebral subluxation remains an under-diagnosed cause of neck and back pain [20]. Common to all concepts or definitions of vertebral subluxation are some form of biomechanical dysfunction and the neurological implications of the biomechanical dysfunction [21,22]. This includes spinal and postural structural displacements as rotations or translations away from normal spinal alignment in any of the three anatomical planes accompanied by pain or neurologic dysfunction. Correction of vertebral subluxations toward a healthy spinal alignment can alleviate the associated pain or neurologic dysfunction [23-26]. Many chiropractic techniques claim to produce structural correction of the spine. However, very few support their claims with clinical scientific evidence in the form of randomized and non-randomized clinical control trials with proper follow-ups. Chiropractic BioPhysics® (CBP®) technique is a full-spine and posture rehabilitation approach to correcting poor posture, deviation of normal spinal alignment and subluxation through incorporating mirror image® exercise, adjustments, and traction procedures [27-31]. CBP® has an extensive amount of quality scientific evidence supporting reliable correction of spinal and postural misalignment yielding improvements in concomitant neurological, musculoskeletal symptoms, spine movement, and patient disability levels [20,23-26,32,33]. It seems logical to propose that improvements in spinal and neurological health may have a beneficial impact on TL.

Case Report

Clinical features

A 35-year-old white female elementary school teacher presented to the office with the primary complaint of neck and mid-back pain for five years following a head-on motor vehicle collision (MVC) as well as nocturnal polyuria whereas she would need to wake up to urinate four times per night. The patient reported that she took generic, regular strength ibuprofen at bottle-recommended dosages 2 to 3 times per day for the 2 weeks immediately following the MVC. The patient reported that she had not and did not take any other medication. The patient had also sustained three prior MVCs in which she was rear-ended. The patient reported drinking three to five mountain dew soda drinks per day.

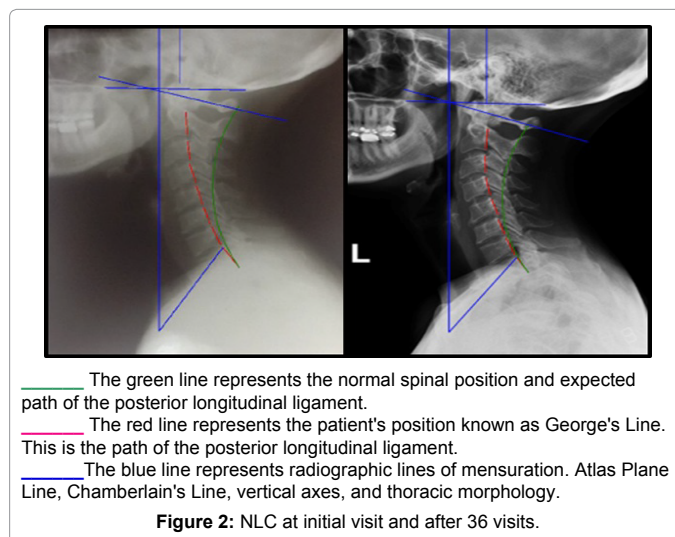
The patient weighed 120 pounds and measured 66 inches tall. She rated her NP and mid-back pain as a 5/10 on the numeric rating scale



#	PF	PRL	ERL	V	EWB	SF	PI	GH	ΔHS
1	50	20	33.33	35	76	62.5	55	45	50
2	95	100	100	75	88	100	90	70	100

PF: Physical Functioning; PRL: Physical Role Limitations; ERL: Emotional Role Limitations; EWB: Emotional Well-Being; V: Vitality; SF: Social Functioning; PI: Pain; GH: General Health; ΔHS: Change in Health Status

Table 1: Health and wellness score initial visit versus after 36 visits sf-36 health survey analysis.



(NRS: 0=no pain; 10=maximum pain). Heart rate variability (HRV) was performed using the CLA Insight™ Pulse Wave Profiler HRV Monitor (Chiropractic Leadership Alliance, Bethany Beach, DE, USA) and the patient scored 75.35 on the autonomic activity index (AAI) (normal is 80.00 to 100.00) and 55.20(S) on the autonomic balance index (ABI) with increased sympathetic nervous system (S) activity (normal is 80.00(S) to 80.00(P) where P stands for parasympathetic nervous system activity) (Figure 1). Using Health and Wellness Score (FLDC LLC, Cumming, GA, USA) to administer, score, and analyze the Short Form 36-Question (SF-36) health survey, the patient scored a 50/100 in physical function (PF), 20/100 in physical role limitations (PRL), 33.33/100 in emotional role limitations (ERL), 35/100 in vitality (V), 76/100 in emotional well-being (EWB), 62.5/100 in social functioning (SF), 55/100 in pain (PI), 45/100 general health (GH), and 50/100 in change in health status (ΔHS) (Table 1). The scoring of the SF-36 indicates that 0/100 in a quality of life (QoL) domain represents the poorest possible result and 100/100 indicates the best possible result. Taking this into account, higher scores indicate better QoL. For comparison, a score of 50 is considered average based on a large United States nationwide population of healthy individuals. The patient had her blood drawn and analyzed for TL. The patient's telomere value was 73 and is a calculation of the patient's TL derived from nucleated white blood cells obtained from whole blood.

Postural and radiographic analysis

Posture analysis [27] revealed a forward head translation (+TzH). Anterior-to-posterior (AP) and neutral lateral cervical (NLC) radiographs were taken and analyzed using PostureRay® Electronic Medical Records (EMR) Software (PostureCo, Inc., Trinity, FL, USA) according to the Harrison Posterior Tangent method for sagittal spine views [34-36] and analyses for frontal spine views (Figure 2) [37]. These examination and analysis methods are valid [38-42], reliable, and repeatable [34-38], as is posture [38].

Measurement	Normal values	Xray 1 values	Xray 2 values
C1 to Horizontal	-29.0°	-20.2°	-25.0°
RRA C2-C3	-10.0°	-2.2°	-6.1°
RRA C3-C4	-8.0°	-9.9°	-9.6°
RRA C4-C5	-8.0°	-0.3°	-6.9°
RRA C5-C6	-8.0°	-1.5°	-1.0°
RRA C6-C7	-8.0°	-4.9°	-3.4°
RRA C7-T1	-8.0°	-11.9°	-8.0°
ARA C2-C7	-42.0°	-18.8°	-27.0°
Tz C2-C7	0.0 mm	24.0 mm	17.7 mm

RRA: Relative rotational angle; the angle between the lines tangent to the posterior vertebral body margins of adjacent vertebrae in the sagittal view; ARA: Absolute rotational angle; the angle between the lines tangent to the posterior vertebral body margins of the limits of a spinal region (cervical, thoracic, or lumbar) in the sagittal view; Tz: Translation in the z axis; the distance of translation of one vertebra with respect to another in the sagittal view

Table 2: Posture ray® emr initial visit versus after 36 visits radiographic analysis.

The AP cervico-thoracic view revealed a spinal alignment within normal limits (WNL). The NLC view (Figure 2) revealed forward head posture (Tz C2-C7) of 24.0 mm (ideal is 0.0 mm and average is 15 mm), an atlas plane line (APL) of -20.2° (ideal is -29.0° and average is 23°), and an absolute rotational angle from C2 to C7 (ARA C2-C7) of -18.8° (normal is -42.0° and average is 34°) (Table 2).

Intervention

The patient was seen for 36 visits over 5 months per CBP® technique protocols incorporating Mirror Image® exercises, adjustments, and traction to correct the cervical hypolordosis and +TzH. Chiropractic care consisted of full-spine chiropractic adjustments and CBP® Mirror Image® drop table adjustments, exercises, and traction at each visit. Mirror Image® refers to the patient being placed into an opposite, over-corrected posture prior to adjustment, as a sustained hold for traction, and as an exercise to facilitate spinal alignment and posture correction. Paraspinal stimulation was administered via the hand-held Impulse® adjusting instrument (Neuromechanical Innovations, Chandler, AZ, USA). The Impulse® adjusting instrument delivers a consistent programmed thrust to stimulate the most mechanoreceptors and proprioceptors possible to relay the position of the body to the brain to retrain the patient's central nervous system (CNS) to adapt to normal posture according to the Harrison Spinal Model. Twenty repetitions of Mirror Image® cervical extension correction exercises were performed 3 times per week. Mirror Image® exercises "attempt to re-train the physiologic adaptations of the soft tissues of the spine by frequently stressing these tissues favoring the optimum loading position balance" [43]. The Cervical Denneroll™ Spinal Orthotic (Denneroll Pty Ltd, New South Wales, Australia) was used for Mirror Image® cervical extension traction at 15 minutes per session per visit. A long-duration of deformation forces counter those that are habituated to a patient's abnormal posture [23-26]. The Denneroll is placed in the upper (C2-C4), middle (C4-C6), or lower (C6-T1) cervical region depending on the patient's cervical alignment.

Results

The patient stated that she maintained her lifestyle throughout chiropractic care. After the 36 visits, the patient was re-assessed. The patient reported that her neck and mid-back pain were reduced from NRS 5/10 to <1/10. HRV was performed again and the patient improved to 80.38 on AAI (normal is 80.00 to 100.00) and 88.51(S) on ABI (normal is 80.00(S) to 80.00(P)) (Figure 1). On the SF-36, the patient improved in all QoL domains to 95/100 in PF, 100/100 in PRL, 100/100 in ERL, 75/100 in V, 88/100 in EWB, 100/100 in SF, 90/100 in

PI, 70/100 in GH, and 100/100 in ΔHS (Table 1). Higher scores indicate better QoL. The patient had blood drawn again to assess her TL. Her telomere value increased 8.23% from 73 to 79. NLC x-ray (Figure 2) analysis (Table 2) after 36 visits revealed improvements in Tz C2-C7 from 24.0 mm to 17.7 mm, in APL from -20.2° to -25.0°, and an ARA C2-C7 from -18.8° to -27.0° (Figure 2 and Table 2). The patient reported to be virtually pain-free and had been able to sleep through the night without having to go to the bathroom to urinate.

Discussion

This report documents the successful outcome in a 35-year-old patient with neck and mid-back pain and nocturnal polyuria as well as unhealthy spinal alignment and posture and autonomic dysfunction. Near complete resolution of symptoms was achieved following the correction of spinal alignment and posture using CBP® technique and the application of Mirror Image® chiropractic adjustments, spinal exercises, and spinal traction using the cervical denneroll spinal orthotic.

Certain circumstances and concurrences need to be highlighted within this report. First, the patient did not alter her lifestyle throughout her care. Most notable is that she continued to drink three to five Mountain Dew sodas per day and still yielded the extraordinary health improvements documented. The patient stated that chiropractic care was the only change in her everyday routine. Following correction of the cervical spinal alignment and posture, the patient's HRV improved considerably from a health risk to WNL (Figure 1). "Several cardinal features of chronic critical illness — regardless of the etiology — support the assertion that autonomic dysfunction is a core mechanism underlying the development and perpetuation of multiorgan failure" [44]. This also helps to understand why TL and HRV may be directly related to each other and inversely related to organ failure (i.e., nocturnal polyuria) and why these variables might be related for this current patient. Woody, et al reported "greater reductions in HRV in response to a stressor are associated with shorter relative TL (i.e., greater cellular aging)" [45]. Additionally, improvements in objective health measures (spinal alignment and posture, HRV, nocturnal polyuria, and TL) are directly related to the subjective improvements in the patient's health (pain NRS and QoL).

Chiropractic care is popularly known as care for neck and back pain. However, this does not explain the neurological and visceral implications within this report. Conduction of an action potential along the spinal cord and nerve fibers is accompanied by shortening and swelling of the nerve [46]. Sagittal cervical deformities and vertebral subluxations are orthopedic abnormalities that apply abnormal tensile forces in the brain stem, cranial nerves 5-12, spinal cord, and nerve roots. This increased tension provides resistance against the necessary shortening and swelling of nerve fibers that accompany an action potential. This tension can give rise to local and distant signs and symptoms including neuralgias, spasticity, dizziness, bladder dysfunction, cervical and lumbar spondylosis, disk hernias, trauma to the spinal cord, and autoimmune disorders [23-26,32,33,47]. This serves as a proposed mechanism for the source of this patient's health conditions due to their resolution following sagittal cervical spinal correction. According to Uchida et al, "adequate correction of local sagittal (cervical) alignment may help to maximize the chance of neurological improvement" [48]. Additionally, patients under long-term chiropractic care demonstrate higher serum thiol antioxidant levels responsible for reducing oxidative stress on the body, facilitating DNA repair enzyme activity which is directly related to health longevity [49].

One limitation to report is that this is a case study (n=1) and no long-term follow-up is presented; as such it does not allow correlation or causation. This is a prospective case study and as such does not lend itself to selection bias. Another limitation is that multiple interventions were applied to the patient. As such, it is unclear which intervention or combination thereof had the positive impact on the patient's health measures. And, while spinal manipulation and exercise have not been shown to reliably correct spinal alignment [31,50-52], there may lie a reliable combination of therapies within permutations of Mirror Image® exercises, adjustments, and traction [23-26].

Conclusion

Our case suggests, for the first time, that cervical spinal alignment and posture may be directly related to TL (health longevity) and that correction thereof may have a directly related effect on health longevity as represented by TL. This case adds more evidence to claims that cervical spinal alignment may also improve autonomic function (HRV and bladder function), QoL, and neck and back pain. As cervical spinal alignment and posture improved, so did the listed health measures. Randomized clinical controlled trials involving measuring TL of a large population of chiropractic patients should be conducted. Hopefully this case report will serve as a motivation for higher levels of evidence from which correlations and causations regarding the effects that chiropractic spinal corrective care might have on health longevity can be made.

Acknowledgements

We would like to acknowledge the Foundation for Vertebral Subluxation (FVS, Kennesaw, GA, USA) for their financial contributions in funding laboratory costs for this case study and Chiropractic BioPhysics® NonProfit (A spine research foundation in Eagle, ID, USA) for their support.

References

- Aviv A (2008) The epidemiology of human telomeres: Faults and promises. *J Gerontol A Biol Sci Med Sci* 63: 979-983.
- Rizvi S, Raza ST, Mahdi F (2014) Telomere length variations in aging and age-related diseases. *Curr Aging Sci* 7: 161-167.
- Bojesen SE (2013) Telomeres and human health. *J Intern Med* 274: 399-413.
- Wong JM, Collins K (2003) Telomere maintenance and disease. *Lancet* 362: 983-988.
- Kong CM, Lee XW, Wang X (2013) Telomere shortening in human diseases. *FEBS J* 280: 3180-3193.
- Snetselaar R, van Moorsel CH, Kazemier KM, van der Vis JJ, Zanen P, et al. (2015) Telomere length in interstitial lung diseases. *Chest* 148: 1011-1018.
- Brouillette S, Singh RK, Thompson JR, Goodall AH, Samani NJ (2003) White cell telomere length and risk of premature myocardial infarction. *Arterioscler Thromb Vasc Biol* 23: 842-846.
- van der Harst P, van der Steege G, de Boer RA, Voors AA, Hall AS, et al. (2007) Telomere length of circulating leukocytes is decreased in patients with chronic heart failure. *J Am Coll Cardiol* 49: 1459-1464.
- D'Mello MJ, Ross SA, Briel M, Anand SS, Gerstein H, et al. (2015) Association between shortened leukocyte telomere length and cardiometabolic outcomes: Systematic review and meta-analysis. *Circ Cardiovasc Genet* 8: 82-90.
- Goglin Se, Farzaneh-far R, Epel Es, Lin J, Blackburn EH, et al. (2016) change in leukocyte telomere length predicts mortality in patients with stable coronary heart disease from the heart and soul study. *PLoS One* 11: e0160748.
- Harley CB, Futcher AB, Greider CW (1990) Telomeres shorten during ageing of human fibroblasts. *Nature* 345: 458-460.
- Babizhayev MA, Savel'yeva EL, Moskvina SN, Yegorov YE (2011) Telomere length is a biomarker of cumulative oxidative stress, biologic age, and an independent predictor of survival and therapeutic treatment requirement associated with smoking behavior. *Am J Ther* 18: e209-226.
- Ludlow AT, Ludlow LW, Roth SM (2013) Do telomeres adapt to physiological stress? Exploring the effect of exercise on telomere length and telomere-related proteins. *Biomed Res Int* 2013: 601368.
- Denham J, O'Brien BJ, Charchar FJ (2016) Telomere length maintenance and cardio-metabolic Disease prevention through exercise training. *Sports Med* 46: 1213-1237.
- Guan JZ, Guan WP, Maeda T, Makino N (2012) Effect of vitamin E administration on the elevated oxygen stress and the telomeric and subtelomeric status in Alzheimer's disease. *Gerontology* 58: 62-69.
- Freitas-Simoes TM, Ros E, Sala-Vila A (2016) Nutrients, foods, dietary patterns and telomere length: Update of epidemiological studies and randomized trials. *Metabolism* 65: 406-415.
- Conklin Q, King B, Zanesco A, Pokorny J, Hamidi A, et al. (2015) Telomere lengthening after three weeks of an intensive insight meditation retreat. *Psychoneuroendocrinology* 61: 26-27.
- Zhao Z, Pan X, Liu L, Liu N (2014) Telomere length maintenance, shortening, and lengthening. *J Cell Physiol* 229: 1323-1329.
- Dagenais S, Haldeman S (2002) Chiropractic. *Prim Care* 29: 419-437.
- Moustafa IM, Diab AA (2015) The effect of adding forward head posture corrective exercises in the management of lumbosacral radiculopathy: A randomized controlled study. *J Manipulative Physiol Ther* 38: 167-178.
- Kent C (1996) Models of Vertebral Subluxation: A Review. *J Vert Sublux Res* 1: 1-7.
- Vernon H (2010) Historical overview and update on subluxation theories. *J Chiropr Humanit* 17: 22-32.
- Moustafa IM, Diab AA, Harrison DE (2017) The effect of normalizing the sagittal cervical configuration on dizziness, neck pain, and cervicocephalic kinaesthetic sensibility: A 1-year randomized controlled study. *Eur J Phys Rehabil Med* 53: 57-71.
- Moustafa IM, Diab AA, Harrison DE (2016) Does rehabilitation of cervical lordosis influence sagittal cervical spine flexion extension kinematics in cervical spondylotic radiculopathy subjects? *J Back Musculoskelet Rehabil*.
- Moustafa IM, Diab AA, Taha S, Harrison DE (2016) Addition of a sagittal cervical posture corrective orthotic device to a multimodal rehabilitation program improves short and long-term outcomes in patients with discogenic cervical radiculopathy. *Arch Phys Med Rehabil* 97: 2034-2044.
- Moustafa IM, Diab AA, Harrison DE (2015) Does improvement towards a normal cervical sagittal configuration aid in the management of lumbosacral radiculopathy: A randomized controlled trial Proceedings of the 13th World Federation of Chiropractic Biennial Congress / ECU Convention.
- Harrison DD, Janik TJ, Harrison GR, Troyanovich S, Harrison DE, et al. (1996) Chiropractic biophysics technique: A linear algebra approach to posture in chiropractic. *J Manipulative Physiol Ther* 19: 525-535.
- Oakley PA, Harrison DD, Harrison DE, Haas JW (2005) Evidence-based protocol for structural rehabilitation of the spine and posture: Review of clinical biomechanics of posture (CBP) publications. *J Can Chiropr Assoc* 49: 270-296.
- Harrison DE, Harrison DD, Haas JW (2002) Structural Rehabilitation of the Cervical Spine. Harrison CBP® Seminars Inc, Evanston, Wyoming, United States.
- Harrison DE, Betz JW, Harrison DD, Haas JW, Oakley PA, et al. (2007) CBP structural rehabilitation of the lumbar spine. Harrison Chiropractic BioPhysics Seminars, Inc.
- Berry RH, Oakley PA, Harrison DE (2017) Alleviation of chronic headaches by correcting lateral head translation posture (-txh) using chiropractic biophysics and berry translation traction. *J Vert Sublux Res* 2017: 87-92.
- Moustafa IM, Diab AA (2015) The addition of upper cervical manipulative therapy in the treatment of patients with fibromyalgia: A randomized controlled trial. *Rheumatol Int* 35: 1163-1174.
- Moustafa IM, Diab AA (2014) Multimodal treatment program comparing 2 different traction approaches for patients with disco genic cervical radiculopathy: A randomized controlled trial. *J Chiropr Med* 13: 157-167.
- Jackson BL, Harrison DD, Robertson GA, Barker WF (1993) chiropractic biophysics lateral cervical film analysis reliability. *J Manipulative Physiol Ther* 16: 384-391.

35. Harrison DE, Harrison DD, Cailliet R, Troyanovich SJ, Janik TJ, et al. (2000) Cobb method or harrison posterior tangent method: Which is better for lateral cervical analysis? *Spine* 25: 2072-2078.
36. Harrison DE, Holland B, Harrison DD, Janik TJ (2002) Further reliability analysis of the harrison radiographic line drawing methods: Crossed ICCs for lateral posterior tangents and Ap modified risser-ferguson. *J Manipulative Physiol Ther* 25: 93-98.
37. Troyanovich Sj, Harrison De, Harrison Dd, Harrison so, Janik Tj, et al. (2000) Chiropractic biophysics digitized radiographic mensuration analysis of the anteroposterior cervico-thoracic view: A reliability study. *J Manipulative Physiol Ther* 23: 476-482.
38. Harrison DE, Harrison DD, Colloca CJ, Betz JW, Janik TJ, et al. (2003) Repeatability over time of posture, x-ray positioning, and x-ray line drawing: An analysis of six control groups. *J Manipulative Physiol Ther* 26: 87-98.
39. Harrison DD, Janik TJ, Troyanovich SJ, Holland B (1996) Comparisons of lordotic cervical spine curvatures to a theoretical ideal model of the static sagittal cervical spine. *Spine* 21: 667-675.
40. Harrison DD, Janik TJ, Troyanovich SJ, Harrison DE, Colloca CJ (1997) Evaluations of the assumptions used to derive an ideal normal cervical spine model. *J Manipulative Physiol Ther* 20: 246-256.
41. Harrison DD, Harrison DE, Janik TJ, Cailliet R, Haas JW (2004) Modeling of the sagittal cervical spine as a method to discriminate hypo-lordosis: Results of elliptical and circular modeling in 72 asymptomatic subjects, 52 acute neck pain subjects, and 70 chronic neck pain subjects. *Spine* 29: 2485-2492.
42. McAviney J, Schulz D, Richard Bock R, Harrison DE, Holland B (2005) Determining a clinical normal value for cervical lordosis. *J Manipulative Physiol Ther* 28: 187-193.
43. Troyanovich SJ, Harrison DD (1996) Chiropractic biophysics (CBP) technique. *Chiropr Tech* 8: 30-35.
44. Toney A, Whittle J, Ackland GL (2013) Autonomic dysfunction is the motor of chronic critical illness. *Annual Update in Intensive Care and Emergency Medicine*: 199-209.
45. Woody A, Hamilton K, Livitz IE, Figueroa WS, Zoccola PM (2017) Buccal telomere length and its associations with cortisol, heart rate variability, heart rate, and blood pressure responses to an acute social evaluative stressor in college students. *Stress*: 1-30.
46. Tasaki I, Iwasa K (1980) Shortening of nerve fibers associated with propagated nerve impulse. *Biochem Biophys Res Commun* 94: 716-720.
47. Breig A (1978) Adverse Mechanical Tension in the Central Nervous System: An Analysis of Cause and Effect; Relief by Functional Neurosurgery. Almqvist and Wiksell International, Stockholm, Sweden.
48. Uchida K, Nakajima H, Sato R, Yayama T, Mwaka ES, et al. (2009) Cervical spondylotic myelopathy associated with kyphosis of sagittal sigmoidal alignment: Outcome after anterior or posterior decompression. *J Neurosurg Spine* 11: 521-528.
49. Campbell CJ, Kent C, Banne A, Amiri A, Pero RW (2005) Surrogate indication of DNA repair in serum after long term chiropractic intervention a retrospective study. *J Vert Sublux Res* 2005: 1-5.
50. Hyrsomallis C, Goodman C (2001) A review of resistance exercise and posture realignment. *J Strength Cond Res* 15: 385-390.
51. Plaugher G, Cremata EE, Phillips RB (1990) A retrospective consecutive case analysis of pretreatment and comparative static radiological parameters following chiropractic adjustments. *JMPT* 13: 198-506.
52. Hurwitz EL, Aker PD, Adams AH, Meeker WC, Shekelle PG (1996) Manipulations and Mobilization of the cervical spine: A systematic review of the literature. *Spine* 21: 1746-1759.