

Class IV Laser Therapy CASE STUDY REPORTS

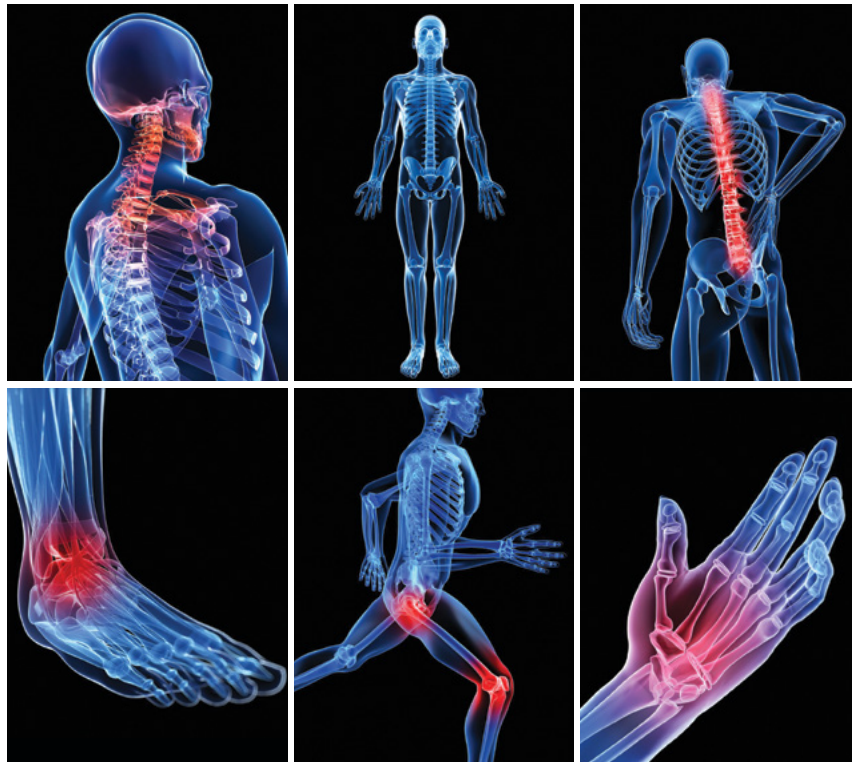

TABLE OF CONTENTS

Achilles Tendinitis: Treatment of Achilles Tendinitis with Class IV Infrared (980 nm) Therapeutic Laser	2
Ankle Sprain: Modality Management of an Acute Ankle Sprain in a Professional Baseball Player: Case Report.....	6
Back: Class IV Laser Therapy: Effective for Back and Neck/Shoulder Pain	10
Back: Class IV Laser Therapy Treatment of Multifactorial Lumbar Stenosis With Low Back and Leg Pain.....	11
Back: The Importance of Treating Patients and Not Images in the Management of Chronic Back and Leg Pain	12
Disc Herniation: Treatment of an Acute Disc Herniation Resulting in Radiculopathy and Foot Drop Using High Power Laser Therapy	14
Fibromyalgia: Effects of Class IV Laser Therapy on Disease Impact and Function in Women with Fibromyalgia	16
Headache: Cervicogenic or Vertebrogenic Headaches	17
Neck: Neck Pain Dynamically Induced Chronic Cord Compression and Radiculopathy	18
Neuropathy: Polyneuropathy Treated with Class IV Therapy Laser	19
Neuropathy: The Long Term Management of Diabetic Neuropathy with High Power Laser Therapy (HPLT)	23
Neuropathy: The Treatment of Chronic Refractive Radiculopathy with High Power Laser Therapy	25
Shoulder: Case Study Looking at the Effect of Class IV Laser on a Patient with Recent Post-Surgical Repair of a Complete Rotator Cuff Tear	27
Shoulder: Shoulder Pain Subacromial Impingement.....	29
TMJ: Resolving TMJ with Class IV Laser Therapy	30
Tendinosis: A Randomized Controlled Trial for the Efficacy of Therapeutic Class IV Laser Treatment for Tendinosis	34
Wound: Effects of 980 nm Wavelength Infrared Laser Exposure in a Cellular Model of Wound Healing	35

TREATMENT OF ACHILLES TENDINITIS WITH CLASS IV INFRARED (980 NM) THERAPEUTIC LASER

Author: Jerry Koziej, DC

CLASS IV LASER THERAPY CASE REPORT

OBJECTIVE:

To describe the clinical management of Achilles tendinitis by using a “high-power” Class IV therapeutic laser.

CLINICAL FEATURES:

This is a case of a fifty-eight year old woman, 5’4”, 155 lbs., presenting with bilateral Achilles tendon pain, the left foot for two years, the right for one year. She did not respond to physical therapy or steroid injections. Rest relieved the pain, weight bearing activity increased the pain. There was pain on palpation over her Achilles tendons. She showed decreased ankle dorsiflexion¹, and displayed genu valgum and foot pronation¹⁰. Resisted neutral position isometric dorsiflexion and active eccentric dorsiflexion exacerbated the pain. Passive eccentric dorsiflexion did not exacerbate the pain. The patient filled out a VAS describing her “worst” pain, “best” pain, and pain “now.” This was filled out on each visit. The patient was accepted for laser therapy.

INTERVENTION AND OUTCOME:

The laser used was the Avicenna class IV infrared laser, model AVI HP-7 5, continuous wave (non-pulsing). The laser emits a visible red beam at 635 nm wavelengths, and an infrared laser beam at 980 nm wavelength¹². The power used was 7.5 watts; the dose was 2250 joules; the area was 15 cm; the energy density was .5 w/cm²; the treatment time was 5 minutes per side and the treatment distance was 2 cm. Treatment distance was ensured by securing the laser wand stylus to maintain the treatment distance. The stylus was kept in light contact with the patient. A swatch of cotton fabric was placed over the tendon with a 3x5 cm hole cut from it to allow for consistent laser treatment area. One open end was placed over the Achilles insertion, and extending proximally. The patient showed significant reduction in pain as indicated by the VAS scores, and significant increase in dorsiflexion flexibility as measured after four sessions with a goniometer.

CONCLUSION:

This case demonstrates the potential benefit of conservative management for Achilles tendinitis with the utilization of “high-power” Class IV therapeutic laser technology to decrease the symptoms associated with Achilles tendinitis.

KEY WORDS:

Class IV laser; Achilles tendonitis; laser therapy; Avicenna laser.

INTRODUCTION:

All providers of health care are under significant pressure to demonstrate efficacy of treatment the FDA provided clearance of the use of “Low-Level” Class III therapeutic

lasers in 2002 and “High Power” Class IV therapeutic lasers in 2004. Since that time, the use of therapeutic lasers technology for the treatment of musculoskeletal conditions has grown in popularity. Although many articles have been written on the topic of laser therapy, and its application for somatic pain conditions, there is a lack of scientific papers that utilize any of the outcome assessments that are required in today’s evidence – based healthcare environment. This paper is the first in a series to utilize generally accepted outcome assessments to determine the effectiveness of a “High-Power”, Class IV laser therapy treatment protocol in reducing the symptoms of chronic somatic pain. The Achilles tendon is the largest and strongest tendon in the body, and one of the most frequently injured tendons^{1,2,17}. Risk factors include decreased dorsiflexion, hyperpronation, and presence of Haglund’s deformity, age, overuse and genetics.^{1,2,11}. Generally, Haglund’s bump can cause direct mechanical pressure on the tendon during exercise. Age related loss of flexibility is a risk factor; most ruptures occur in athletes in their 30’s and 40’s, and Type O blood types have a congenitally higher risk of Achilles problems². Systemic diseases such as Reiter’s syndrome can predispose one to Achilles tendon symptoms^{2,11}.

Sudden pain slightly proximal to the calcaneal insertion is suggestive of major tear or rupture. Slowly occurring pain is indicative of tendonitis⁸.

Michaud¹⁰ states that the medial aspect of the Achilles tendon in those possessing forefoot valgus deformity is prone to injury during static standing. The everted calcaneus places a constant tensile strain in the medial aspect of the tendon. This prolonged traction produces vascular impairment that may predispose the tendon to subsequent degenerative changes.

Achilles tendinitis will respond to conservative care. This includes transverse friction massage, taping, use of orthotics and stretching^{8,11, 16}. Insertional Achilles tendon problems can benefit from transverse friction massage, non insertion can benefit from stretching of the triceps surae group^{2, 8}. Phonophoresis with steroid gel, NSAIDS, and cortisone injections are also used^{12, 13, 15}. Surgery or casting may be indicated for rupture or refractory cases^{8, 9, 11}.

Steroid injection has long been a method of treatment for tendinitis in general, and Achilles tendinitis in particular. However, it is commonly known that steroid injections are injurious to tissue. Hays, et al.¹³ recommends steroid injection for tendinitis except the Achilles tendon. Csizy and Hinterman¹⁴ state that steroid injection increases the risk of tendon ruptures, and that despite this, clinicians routinely inject Achilles tendons. Rees, et al.,¹⁵ stress the degenerative nature of tendon disorders as opposed to the inflammatory nature. Tam⁴ reported on changes in

PE2 synthesis into PE12 under influence of low level laser therapy (LLLT), and Bjordal³ used microdialysis measurement of Achilles peritendinous prostaglandin E2 concentrations pre- and post- LLLT and found a decrease in PE2 concentrations after laser therapy, implying the presence of the inflammatory component of tendinitis along with the degenerative component. Mizutani, et al. also found decreased PGE2 levels post LLLT (830 nm, 10 treatments) and associated PGE2 levels with nociceptive pain⁵.

Fillipin, et al., found using LLLT (904 nm wavelength, 5 joules/cm²) markedly decreased histological abnormalities in rats with traumatized Achilles tendons as compared to the controls¹⁸.

CASE REPORT:

A fifty-seven year old woman presented to this office with the complaint of Achilles tendon pain, bilaterally, the left of two years duration, and the right for one year. The pain was located over the insertion of the Achilles tendon. She had a history of arthroscopic knee surgery, bilaterally, a thirty five year smoking habit. She had no history of foot or ankle injury. She could not recall any mechanism of onset. She had had a course of physical therapy, and two steroid injections in her left Achilles tendon, and one in her right. She said the first injections gave her two week's relief, the second in her left one week. Weight bearing activity exacerbated the pain, rest relieved it. Pain levels were lower at commencement of activity, worsening with prolonged activity. NSAIDS did not relieve the pain. There was no pattern during the day related to her pain levels. The patient was 5'4", 220 pounds. She ambulated with difficulty, slowly and looked to be in distress. Inspection revealed tenderness to palpation over the distal Achilles tendon. Her Q angle measured 20 degrees bilaterally, and she displayed genu valgum. Her blood type is B positive². Static stance showed a medial displacement of her Achilles tendon indicating pronation. Dorsiflexion was 10 degrees for both right and left. Algometric exam was inconclusive. The patient was presented with a 10 cm visual analog scale (VAS). The patient was asked to rate her pain in terms of "worst pain," "best pain," and "pain right now." These pain ratings were as of her last steroid injection. The worst pain for her left was 8.5; right, 9. The best pain for her left was 5; her right, 6. At the time of exam, the left was 5; the right, 6. The patient was accepted for laser therapy.

The laser used was the Avicenna class IV infrared laser, model AVI HP-7 5, continuous wave (non-pulsing). The laser emits a visible red beam at 635 nm wavelength, and an infrared laser beam at 980 nm wavelength¹². The power used was 7.5 watts; the dose was 2250 joules (150 joules/cm²); the area was 15 cm; the energy density was .5 w/cm²; the treatment time was 5 minutes per side and the treatment distance was 2 cm. Treatment distance was ensured by securing the laser wand stylus to maintain the treatment distance. The stylus was kept in light contact with the patient. A swatch of cotton fabric was placed over the tendon with a 3x5 cm hole cut from it to allow for consistent laser treatment area. One open end was placed over the Achilles insertion and extending proximally.

The patient received four laser treatments over each Achilles tendon. VAS scores prior to the second session were:

Left: worst: 8; best: 6; now: 6
Right: worst: 3; best: 3; now: 3
Prior to the third session:

Left: worst: 5; best: 5; now: 5
Right: worst: 3; best: 1; now: 1
Prior to the fourth session:

Left: worst: 4; best: 0; now: 0.
Right: worst: 0; best: 0; now: 0.

One week later the patient scored her VAS.

Left: worst: 3; best: 0; now: 0.
Right: worst: 0; best: 0; now: 0.

Dorsiflexion was 15 for the left and 20 deg for the right.

DISCUSSION:

A review of the literature shows laser therapy enhances physiologic repair without toxicity, leading to local and systemic effects³². There are a number of physiological changes that take place under the influence of infrared radiation. The therapeutic effects are well known but not all the mechanisms are known. Infrared radiation may reduce pain and improve function through reduction of inflammation through its influence on prostaglandins. Prostaglandins are moderators of hormonal activity, and have a role in inflammation²⁹. Bjordal, et al. measured the levels of prostaglandin E2 concentrations in the peritendinous areas of patients who had Achilles tendinitis. Measurements were taken pre- and post-treatment by LLLT (904 nm wavelength, 20mW/cm²) and found to be lower after treatment, as were pain levels³. Tam⁴ suggested that LLLT acts on prostaglandin synthesis, increasing the change of PG2 into PG12. PG12 is the main product of arachidonic acid in the endothelial cells and smooth muscle cells of vessel walls and that have a vasodilating and anti-inflammatory action. Mizutani, et al. also found decreased PGE2 levels post LLLT (830 nm, 10 treatments) and associated PGE2 levels with nociceptive pain⁵. Ferreira, et al. injected PG2 into Wistar rats to induce hyperalgesia and found that LLLT (632 nm wavelength, 2.5 J/cm²) increased pain threshold (algometric examination) and reduced edematous tissue by 54% (using plethysmography). In addition, this study found that LLLT inhibits sensitization by its effect on nociceptors of the inflammatory process rather than an effect on opioid receptors²². Fillipin, et al., found using LLLT (904 nm wavelength, 5 joules/cm²) markedly decreased histological abnormalities in rats with traumatized Achilles tendons as compared to the controls¹⁸. Laasko, et al. also induced inflammation in Wistar rats and found LLLT effective but that the effectiveness was dose-specific. A dose of 1 J/cm² was not effective, but that 2.5 J/cm² was. The control animals showed normal beta-endorphin containing lymphocytes, but no beta-endorphin containing lymphocytes in those irradiated at 2.5 J/cm²²¹.

Giuliani, et al. described other models of pain and edema reduction. Acute and chronic inflammation was induced using injection of carrageenan and Complete Freund's Adjuvant (CFA, a water oil emulsion containing inactivated

mycobacteria used to boost immune system in animals and induce inflammation), respectively. Neuropathic pain was produced by sciatic nerve chronic constriction injury (CCI). Very low laser therapy (vLLLT) was used on the animals. It was found that vLLLT reduced edema and pain in the acute and chronic inflammation if laser was administered at acupuncture points. Spontaneous pain and thermal hyperalgesia were reduced in CCI rats treated with vLLLT. Their conclusion was that enkephalin mRNA level was strongly upregulated in the external layers of the dorsal horn of the spinal cord in the CFA and CCI, and that vLLLT increased the mRNA level in single neurons^{20,29}.

Infrared laser therapy has been shown to be effective on wound healing itself through its effect on blood flow by dilatation of blood vessels. Bjordal describes vessel dilation through its effect on synthesis of PG12³. Nitrosyl complexes of heme proteins, such as hemoglobin and cytochrome c are the primary chromophores of laser radiation. When irradiated they dissociated to produce free nitric oxide which may be responsible for blood vessel relaxation. Klebenov, et al. compared activity of wound exudate leukocytes (from rat skin) to see if laser – coherent light – and light emitting diode radiation (LED) – non-coherent light – had an effect on functional wound activity. It was that both the laser and LED radiation stimulated the transition from the inflammatory phase to the reparative (proliferative) phase. Vladimirov, et al. also describe the possible effects on leukocytes, fibroblasts, keratinocytes, and endotheliocytes. Molecularly, LLLI (sic) stimulates mitochondrial membrane potential (MMP), cytokine secretion and cell proliferation. Gavish, et al, used a 780 nm titanium-sapphire laser (2 J/cm²) and measured MMP, cytokine gene expression, and subcellular localization of promyelotic leukemia (PML, a cell-cycle marker) pre and post laser application. MMP increased; expression of interleukin-1 alpha, interleukin-6, and keratinocytes growth factor were transiently upregulated. However, the expression of the pro-inflammatory gene interleukin-1 beta was suppressed. The subnuclear distribution of PML was altered from discrete domains to its dispersed form within an hour after LLLI. These changes reflect an activated stage in cell cycle promoting proliferation and suppression of inflammation^{20,27,30}. Laser light may membrane functional properties: changes in the activity of membrane ion pumps hence ion flow. Borotetto, et al also found mitochondrial membrane potential changes after laser irradiation for varying lengths of time (energy density 100 mJ/cm²)^{26,31}.

Hopkins, et al demonstrated enhanced healing of superficial wounds using LLLT, (8 J/cm²) in a triple-blind, sham controlled study of 22 subjects. Wound healing appeared to be enhance by facilitating fibroplasias and wound contraction³⁴. Irradiation (at 660 nm) was found to induce angiogenesis in rats with partially ruptured Achilles tendon²³. Blood vessel numbers were higher post-laser application. Although they dropped later, numbers were still higher than the control groups and their own pre-laser application.

Brossuea, et al. did a meta-analysis on laser trials and the effect on osteoarthritis (OA). They found that three

trials showed no effect on pain levels, two showed beneficial effects, using VAS. In another with no VAS, significantly more patients reported pain relief. One study found significant increased knee range of motion. Lower dosage LLLT was found to be as effective as higher dosage in reducing pain and increasing range of motion. The implication to the authors of the study is that method of application may explain the inconsistent data. On another, Brosseau et al found that laser therapy was no more effective than placebo in providing symptomatic relief for OA in finger joints. These patients received three treatments per week for six weeks. The only differences found in finger range of motion were in carpometacarpal opposition and grip strength^{24,25}.

Some explanations are based on the light absorption by primary endogenous chromophores. These include hemoglobin (porphyrins), cytochrome c, mitochondrial enzymes, and flavins^{3,31}.

Taking in to account the small doses of radiation appropriate for small animals, the material referenced above all involve “cold lasers” or “soft lasers.” The dosages delivered are in the range of .1 to 25 J/cm². The power ranges in the area of 1 W. The class IV laser is powered up to 7.5 W, and the dosage delivered in this case report was 150 J/cm². Tissues able to respond to laser therapy is limited by the penetration of the beam^{12,32}. This may explain the positive response after only four sessions, compared to 10 or more in some of the studies^{5,25}. The depth of biological response is dependent on total power density and power output...Since depth of penetration is dependent only on wavelength. Penetration is greater with longer wavelength, especially with the infrared wavelengths. The Avicenna class IV beam is 980 nm, while the others referenced have wavelengths that are shorter.³³

The same depth value is achieved no matter the power; however, the energy density is much greater with the class IV than the class III models.

CONCLUSION:

Low-level laser therapy appears to be an effective tool in somatic pain and dysfunction. The physiological action of the laser is dependent on the power and wavelength of the laser, and the depth of biological action. The longer wavelength of the class IV laser means better penetration; the higher power delivers a dosage of energy an order of magnitude greater than the “cold laser.” This suggests faster healing of wounds, and suppression of pain and swelling.

ABOUT THE AUTHOR

Dr. Koziej is a native of Dayton, OH and has practiced since 1996. He once rode his bicycle across America and has since remained physically fit. Today he helps competitive athletes and weekend warriors heal through his expertise in biomechanics. Dr. Koziej was one of the first in Kentucky to master Class IV Laser Therapy and utilizes it to complement his expertise in spinal adjusting techniques.

REFERENCES:

1. Hamil, Joseph; Knutzen, Kathleen. *Biomechanical Basis of Human Movement*. Williams & Wilkins, 1995.
2. Baker, C., et al. *The Hughston Clinic Sports Medicine Book*. Williams & Wilkins, 1995
3. Bjordal, JM; Lopes-Martins, RA; Iverson VV. A Randomized, placebo Controlled trial of low level laser therapy for activated Achilles tendonitis with microdialysis measurement of peritendinous prostaglandin E2 concentrations. *Br Jour Sports Med*. 2006 Jan;40(1):76-80.
4. Tam, G. Low power laser therapy and analgesic action. *Jour Clin Laser Med Surgery*. 1999 Feb;17(1): 29-33.
5. Mizutani, K, et al. A clinical study on serum prostaglandin E2 with low-level laser therapy. *Photomed Laser Surg*. 2004 Dec;22(6):537-9.
6. Rygh, L, et al. Molecular mechanisms in acute and chronic pain states. *Tidsskr Nor Laegeforen*. 2005 Sep 8;125(17):2374-7.
7. Miriutova, NF, et al. Laser therapy and electric stimulation in rehabilitation treatment of peripheral neuropathy. *Vopr Kurortol Fizioter Lech Fiz Kult*. 2002 Jul-Aug;(4):25-7.
8. Mootz, et al. *Sports Chiropractic*. Aspen Publications, Inc. 1995.
9. Reiley, Mark A. *Guidelines for Prescribing Foot Orthotics*. Slack, Inc., 1995.
10. Michaud, Thomas, C. *Foot Orthoses and Other Forms of Conservative Foot Care*. Thomas C. Michaud, 1997.
11. Anderson, Carl A. *Office Orthopedics for Primary Care*. W.B. Saunders, 1995.
12. Anderson, Herbert, et al. *A Physicist's Desk Reference*. The American Institute of Physics, 1989.
13. Hayes, D., et al. Tendon pathology in the foot. The use of corticosteroid injection therapy. *Clin Podiatr Med Surg*. 2000 Oct;17(4):723-35.
14. Csizy, M., et al. Rupture of the Achilles tendon after local steroid injection. Case reports and consequences for treatment. *Swiss Surg*. 2001;7(4): 184-9.
15. Rees, JD., et al. Current concepts in the management of tendon disorders. *Rheumatology* (Oxford). 2006 Feb 20; [Epub ahead of print].
16. Aronow, MS. Posterior heel pain (retrocalcaneal bursitis, insertional and noninsertional Achilles tendinopathy). *Clin Podiatr Med Surg North Am*. 2005 Jan;22(1):19-43.
17. Ireland, M., et al. *The Female Athlete*. Saunders, 2002.
18. Fillipin, L, et al. Low-level laser therapy (LLLT) prevents oxidative stress and reduces fibrosis in rat traumatized Achilles tendon. *Lasers Surg Med*. 2005 Oct;37(4):293-3000.
19. Klebenov, G., et al. A comparative study of the effects of laser and lightemitting diode irradiation on the wound healing and functional activity of wound exudates leukocytes. *Biofizika*. 2005 Nov-Dec;50(6):1137-44.
20. Giuliani, A., et al. Very low level laser therapy attenuates edema and pain in experimental models. *Int Jour Tissue React*. 2004;26(1-2):29-37.
21. Laakso, EL; Cabot, PJ. Nociceptive scores and endorphin-containing cells reduced by low-level laser therapy (LLLT) in inflamed paws of Wistar rat. *Photomed Laser Surg*. 2005 Feb;23(1):32-5.
22. Ferreira, DM, et al. Analgesic effect of He-Ne (632.8 nm) low-level laser therapy on acute inflammatory pain. *Photomed Laser Surg*. 2005 Apr;23(2):177-81.
23. Salate, A., et al. Effect of In-Ga-Al-P diode laser irradiation on angiogenesis in partial ruptures of Achilles tendon in rats. *Photomed Laser Surg*. 2005 Oct;23(5):470-5.
24. Brosseau, L., et al. Randomized controlled trial on low level laser therapy (LLLT) in the treatment of osteoarthritis (OA) of the hand. *Lasers Surg Med*. 2005 Mar;36(3):210-9.
25. Brosseau, L., et al. Low level laser therapy (Classes I, II, III) for treating arthritis. *Cochrane Database Syst Rev*. 2003;(2):CD002046.
26. Bortoletto, R. et al. Mitochondrial membrane potential after low-power laser irradiation. *Lasers Med Sci*. 2004;18(4):204-6.
27. Gavish, L., et al. Low level laser irradiation stimulates mitochondrial membrane potential and disperses subnuclear promyelotic leukemia protein. *Lasers Surg Med*. 2004;35(5):396-76.
28. Fessenden, R; Fessenden J. *Organic Chemistry*. Willard Grant Press, 1982.
29. Djouhri, L., et al. Spontaneous pain, both neuropathic and inflammatory is related to frequency of spontaneous firing in intact C-fiber nociceptors. *J Neurosci*. 2006 Jan 25;26(4):1281-92.
30. Vladimirov, I., et al. Molecular and cellular mechanisms of the low intensity laser radiation effect. *Biofizika*. 2004 Mar-Apr;49(2):339-50.
31. Kujawa, J., et al. Effect of low – intensity (3.75-25 J/cm²) near-infrared (810 nm) laser radiation on red blood cell ATPase activities and membrane structure. *J Clin Laser Med Surg*. 2004 Apr;22(2): 111-7.
32. Santana-Blank, LA, et al. Photo-infrared pulsed biomodulation (PIPBm): a novel mechanism for the enhancement of physiologically reparative responses. *Photomed Laser Surg*. 2005 Aug;23(4):416-24.
33. Turner, Jan; Hode, Lars. *Laser Therapy in Dentistry and Medicine*. Prima Books AB, 1996.
34. Hopkins, J., et al. Low-level laser therapy facilitates wound healing in humans: A triple-controlled study. *J Athl Train*. 2004 Jul-Sep; 39(3): 223-229.

MODALITY MANAGEMENT OF AN ACUTE ANKLE SPRAIN IN A PROFESSIONAL BASEBALL PLAYER: CASE REPORT

Authors:

Steve Scher, MSPT, ATC, CSCS, PES

Henry Ford Health System
Center for Athletic Medicine

Kevin Rand, ATC, CSCS

Head Athletic Trainer Detroit Tigers

Steve Carter, ATC

Assistant Athletic Trainer Detroit Tigers

CLASS IV LASER THERAPY CASE REPORT

OBJECTIVE:

To describe two new treatment modalities that improved the healing time of a 33 year old professional baseball player with an acute grade 1 anterior talofibular (ATF) ligament sprain.

BACKGROUND:

Ankle sprains are one of the most common injuries in sporting events. Most of literature supports one week of rehabilitation with a first degree ankle sprain for full recovery. Athletic trainers follow the R.I.C.E. acronym (Rest, Ice, Compression, and Elevation) and use various modalities (such as electrical stimulation) to reduce pain and inflammation.

DIFFERENTIAL DIAGNOSIS:

Ankle fracture and subluxation was ruled out by a medical exam from the visiting team physician. Radiographic images were not performed secondary to the results of the clinical exam. The ankle was point tender over the ATF ligament, with moderate swelling.

TREATMENT:

Treatment focused on decreasing pain and inflammation. Four modalities, including two new ones, were used without therapeutic exercise or manual techniques. Immediate intervention was initiated with a class IV therapeutic laser, polymem bandage, open basket weave tape application, and ice. The athlete returned to play in two days.

UNIQUENESS:

The use of modalities varies greatly between clinicians. This report offers two new ideas to decrease healing time: laser and Polymem bandage. The Avicenna therapeutic class IV laser accelerates the wound healing process and promotes anti-inflammation and pain properties. The Polymem bandage was also used providing a sponge-like application to clear waste products from the injured site.

CONCLUSION:

The use of these new modalities not only reduced the time to return to play, but also reduced the effects of the pathology signs and symptoms observed in this individual case. Research trials are suggested to validate the use of the Avicenna class IV laser and the Polymem bandage.

KEY WORDS:

Class IV Therapeutic laser, ankle sprain, Polymem bandage, open basket weave

INTRODUCTION AND BASIC SCIENCE

Inversion ankle sprains are the most common sprain in athletic events today. Inversion ankle sprains commonly damage the anterior talofibular (ATF) ligament. Inversion ankle sprains are rated in three different degrees. First degree is a partial stretching of the ATF. A second degree inversion sprain is a complete tear of the ATF and a stretch and/or tear of the calcaneofibular (CF) ligament. Lastly, a third degree inversion sprain involves the ATF, CF, and the posterior talofibular ligament¹. Presentation consists of positive clinical signs such as point tenderness, local swelling, discoloration, and pain. Often ankle sprains occur with contact or external force in sporting activities, but frequently foot placement and the surface on which the activity is played has shown to affect the incidence of ankle sprains and injuries. Turf surfaces increase friction and cause injuries without external contact.

The diagnosis of ankles sprains is often from history, mechanism of the injury, and special tests. First degree ankle sprains are mild in severity and usually only involve the ATF ligament and have mild localized pain. Mechanism is associated with ankle inversion and plantar flexion. Anterior drawer and talar tilt special tests are negative. First degree sprain rehabilitation phases are as follows: acute phase 1-3 days, subacute 2-4 days, and rehabilitation phase 7 days².

The history of managing ankle sprains has typically followed a regimen of ice and rest for 1-2 days¹. Modalities such as cryotherapy (ice pack, ice bucket-submersion) use vasoconstriction properties to control effusion. Over the years, taping techniques and wraps have provided compression to reduce swelling. Other modalities such as ultrasound and electrical stimulation have been useful as well to decrease pain and inflammation. Massage techniques, such as effleurage, are used to try to push the edema towards the heart for absorption in the body. This case report outlines new treatment modalities and alternative techniques to managing injuries.

ULTRASOUND, ELECTRICAL STIMULATION, ICE AND COMPRESSION MODALITIES

ULTRASOUND:

Traditionally, pulsed-low intensity mode therapeutic ultrasound is used for acute swelling and inflammation. Pulsed mode of ultrasound uses the non-thermal effects encouraging cavitations and dilation of the tissue cells. The non-thermal effects of ultrasound increases membrane permeability causing a stirring affect. This agitation of the ions in the cell increases the gradient, and ultimately yielding higher diffusion. The parameters for non-thermal ultrasound are an intensity of 1mhz frequency, 50% duty cycle, w/cm², and total treatment time of 10 minutes. Ultrasound has been studied for its effects and potential therapeutic qualities. For the best treatment delivery a 3 degree rise in tissue temperature needs to be achieved to increase metabolic rate and blood flow, reduce chronic inflammation and muscle spasm, and elastic properties. These effects can be achieved by using thermal modes of ultrasound. To be most accurate, ultrasounding two times the total surface of the sound head in a continuous duty cycle is optimal for achieving 3 degrees of tissue temperature rise³. Draper and Ricard (1993 and 1995) reported therapeutic ultrasound has a depth of penetration approximately 2.5 cm into the tissue using 3mhz sound head with a continuous mode for 10 minutes. Using a 1mhz sound head for 10 minutes would achieve a depth penetration of 2.5 to 5 cm during ultrasound treatment. As stated previously when acute swelling is present, a non-thermal mode of ultrasound would be recommended. Nyanzi et al. completed a double-blind randomized controlled trail of the efficacy of using ultrasound to treat lateral ankle sprains. The trail reported that ultrasound is not a better form of treatment when compared to placebo. Conversely, pain perceived and range of motion (dorsiflexion) was statistically significant between the ultrasound and placebo groups.

ELECTRICAL STIMULATION:

Electrical stimulation has shown to be a fairly positive modality to use in controlling acute edema^{6 and 7}. There also have been positive results in controlling and reducing pain with use of electrical stimulation, primarily transcutaneous electrical nerve stimulation (TENS). Micro-stimulation is another mode of electrical stimulation to control edema. Micro-stimulation parameters are as follows: use these parameters 30 frequency, 250-300 intensity, for 20 minutes at a negative polarity for edema control. Interferential or IFC mode can be manipulated to control edema and pain by adjusting the frequency. IFC utilized for edema control is 1-10 Hz for 20 minutes. Pain control using IFC frequency is adjusted to 80-150 Hz for 20 minutes. High Volt stimulation is also helpful in combating acute edema and muscle spasm. Many wavelengths can be modified to help reduce pain and inflammation.

ICE:

Ice is well understood to reduce edema and decrease pain. Ice initiates vasoconstriction properties and the cold numbs the tissue providing an analgesic effect. One study looked the effects of cooling, heat, and contrast baths with first degree and second degree ankle sprains in thirty subjects.

Icing alone was the only modality found to reduce edema⁸. Heat was found to increase swelling and slow recovery in this study.

COMPRESSION:

Compression dressings have always been an option to control the amount of edema controlled in a joint or extremity. Linde F et al. (1984) applied compression bandages for 4 days post-ankle sprain. Two groups were formed, one had no bandages applied and the other had bandages placed on the ankle. The results showed no significant in difference in pain, function, swelling, or limitation of motion between the two groups.

THE NEW CLASS IV LASER AND ALTERNATIVE POLYMEM BANDAGE APPLICATION LASERS:

The Avicenna therapeutic class IV laser (VTR75) is the latest therapeutic modality technology. The Avicenna class IV laser generates 7500 mw (milliwatts) of power within a 980 nm (nanometer) treatment beam. The laser beam treatment depth is approximately 10 cm with a width of 7 cm. The Avicenna therapeutic laser accelerates tissue repair and cell growth, and establishes anti-inflammation and anti-pain properties. First, accelerated tissue repair is achieved by increased cellular reproduction. The cell has a higher uptake of nutrients and gets rid of waste products sooner. Second, the laser decreases inflammation by vasodilatation and activates the lymphatic drainage system. Lastly, the laser's analgesic properties reduce the nerve pain fibers (C fibers) sensitivity by blocking its transmission to the brain. The result of decreased inflammation and edema yields less pain for the athlete.

This device is not to be confused with a low level cold laser. The effectiveness of the low level laser is questionable¹⁰. However, a low level laser or cold laser only has a penetration depth of .5cm. A study by Fung et al.¹¹ evaluated 16 MCL surgical transactions in rats. They concluded that one dose of low level energy laser improved the tensile strength and stiffness of the repairing MCL at 3 and 6 weeks from injury.

POLYMEM BANDAGE:

Polymem bandage was originally developed for wound care, and not the treatment of ankle sprains or closed soft tissue injuries. The Polymem dressing provides a warm and moist optimal environment for healing of tissue. The dressing releases compounds that have been shown to stimulate healing. The dressing also promotes the concentration of the body's nutrients and regeneration of cells to the tissue site it is covering. The Polymem dressing also works as a waste product remover from the tissue while cleaning and moisturizing the application site. The cleansing agent is F-68 Surfactant and the super absorbent starch co-polymer absorbs and holds excess waste fluids and promotes growth to the site. This process is specifically advantageous to an open wound. Although, this dressing was designed for wounds and damaged tissue, acute edema and contusions have been very responsive to this application. This has been observed several times with different athletic injuries. The Polymem dressing when applied immediately to the injured site results in decreased pain and discoloration within 24 hours.

CASE PRESENTATION

A 33 year old male professional baseball player with no previous history of ankle problems sustained an acute ankle injury. The player is 5'11" tall and weighs 195 pounds. The ankle was injured in plantar-flexion and inversion mechanism, while trying to catch a fly ball in the outfield. The player explained that his foot caught on the artificial turf and rolled. The athlete described instant pain without pop and the ankle felt weak. The athlete was unable to continue to play but could walk off the field without assistance. The goal of the player and athletic trainers was to have the player return to play quickly, sustaining the everyday endurance level and movements for his sport demands while avoiding re-injury.

ASSESSMENT

The athlete was brought into the training room for further evaluation. The head and assistant athletic trainers performed special tests, which revealed no laxity of the ATF, CF, PTF, or deltoid ligaments. The anterior drawer, klieger and talar tilt were negative. Squeeze test and tapping revealed negative results for a fracture. On palpation there was tenderness over the ATF ligament. There was minimal-to-moderate swelling over the ATF and ankle mortise. Dorsiflexion was within normal limits and not painful. Plantarflexion of the ankle revealed pain. The diagnosis was then described as a first degree ATF ankle sprain.

TREATMENT

DAY 1:

The athlete was treated with an Avicenna therapeutic class IV laser for 10 minutes at 7.5 watts. The athlete could feel warmth from the laser, but otherwise no pain was reported during the application. Then, a Polymem bandage was applied to help with swelling and pain. The ankle also was treated with an open basket weave taping to be worn overnight. Ice pack was applied 2 times that evening for 15 minute intervals.

DAY 2:

After the 1st day of treatment a minimal amount of discoloration (24 hours later) over the lateral ankle was noted, however, there was no palpable pain over the ATF ligament. The Polymem bandage and basket weave taping was taken off. The Polymem bandage was heavy and moist. Another application of the laser modality was used for 10 minutes, at the previous settings. Ice pack was applied 2 times that day at 15 minute intervals. The athlete may have been able to compete today. The athlete was also suffering from cold like symptoms and thus scratched from the game. The athlete described no pain and minimal soreness.

The athlete was advised to ambulate within comfort levels, but no additional treatments were applied.

DAY 3:

After the 2nd day of treatment, the discoloration was completely gone and there was no palpable tenderness over the ATF. Swelling was also unremarkable. The athlete had a closed basket weave tape application and returned to play. A discharge criterion was the ability to perform figure

eights and cutting maneuvers without pain or apprehension. The athlete played a full professional baseball game without complaint. The athlete was not given an exercise program or proprioception program throughout the 2-3 days. After the game the athlete was iced for 15 minutes. On observation there was no palpable tenderness or swelling noted.

DISCUSSION

First degree anteriortalofibular ligament sprains are common. An athlete with this type of sprain presents with or without swelling or ecchymosis, point tenderness over the ATF ligament, and negative anterior drawer and talar tilt. The ATF ligament is injured commonly with a plantarflexion and inversion roll of the ankle joint. Clinical exam is often enough for an accurate diagnosis. There are many modalities and treatment techniques used to speed up healing time, decrease pain, and reduce swelling in first degree ankle sprain. Treatment varies greatly between clinicians when rehabilitating ankle sprains. However, the efficacy of these modalities is debatable. For example, the problem with cryotherapy could be using a contrast bath versus ice bucket? Answer: The contrast bath has a flushing affect that promotes vasodilatation followed by vasoconstriction creating a circulation paradigm. The ice bucket treatment purely acts a vasoconstrictor and provides analgesic properties (numbing). Many believe that ice also provides increased blood flow after the thawing phase of the ice bucket application. A sound decision and evidence based usage of the modality provides the clinician with the option to use the ice bucket or contrast bath. The problem with ultrasound is that it has minimal effect if the sound head travels in a bigger distance than twice the sound head (covering greater tissue) if you are trying to reach 3 degrees of TTR. The problem with electrical stimulation has shown to be not as effective with athletes who have a lot of adipose tissue. A lot of adipose tissue impedes the current. Finally, the problems with the new cold low level lasers are there poor penetration depth to .5 cm. Ultimately, the area of treatment, the depth, and the goal of the modality needs to be addressed before usage.

The Avicenna therapeutic class IV laser is a new modality and has some definite clinical advantages over other modalities. There have been some positive research results that were cited earlier in this case report. The class IV laser depth of penetration is greater and wider than the other known modalities. Because of the depth of penetration the laser treatment affects intra- and extra-articular peripheral joint tissues. Ultrasound, electrical stimulation, ice and superficial heat applications do not penetrate as deeply. The athlete in this case recovered quickly and without strength loss. From day 1 to day 3, the laser treatments seemed to provide relief for the athlete. Subjectively, the athlete felt better after the treatment. The athlete reported less soreness and pain when walking. From observation the ankle swelling decreased quickly.

The mechanism of action of Polymem bandage on closed injuries is unknown. However, once you use it you may start believing. However, the discoloration that occurs from tissue damage seems to be reduced drastically. The Polymem bandage was soaked with waste possibly

from tissue damage secondary to the ankle sprain. In our experience, this professional baseball player's total injury time was decreased by 50%.

CONCLUSION

In professional sports, the delayed return to play has many implications. One of the goals as the athletic trainer is to facilitate a quicker return to sport for their athletes. The athletic trainer provides a safe rehabilitative environment while avoiding re-injury. One of the primary early rehabilitation care decisions that athletic trainers make is to decide what modality to use to help reduce the initial injury symptoms. Combating the effusion and pain early provides success in achieving symptom reduction. As described in this case study there are many modality applications that can achieve this goal. In theory, many modalities seem to help. Data in the literature supports the use of a particular modality, and there is evidence that does not support its use. Due to the unreliable results with conventional modalities, this case report examines the use and efficacy of the class IV laser and Polymem bandage application. The laser has been recently approved by the FDA and is not yet used commonly in most rehabilitation centers. By the end of 2004 or early 2005 high level lasers will be more readily available and affordable for general practice. The results of this case report suggest favorable preliminary outcomes using the laser and Polymem bandage. We have shown that the use of these two modalities reduced the return to play time, pain, and swelling. Randomized controlled trial research studies are needed to investigate the treatment efficacy of the class IV laser.

Investigating the reliability of depth of penetration, healing time, and reduction of symptoms may strengthen the conclusion using the class IV laser. A study using the class IV laser and a placebo group may also be warranted. The Polymem bandage should also be investigated in a double blind trial to see if there is any evidence for support its use with closed skin tissue damage (i.e. swelling and bruising). This case provides some insight with new treatment modalities. Further research is needed to support the findings in this case report.

ABOUT THE AUTHORS

STEVE SCHER MSPT, ATC, CSCS, PES

Steve is the clinic director at Royal Oak. He has been in practice for 9 years. Steve serves as the physical therapist for the Detroit Lions and a physical therapist consultant for the Detroit Tigers. In 2007, Steve was accepted into the American Society of Shoulder and Elbow Therapists.

Steve Scher, MSPT, ATC, CSCS, PES
Henry Ford Health System
Center for Athletic Medicine
Department of Rehabilitation Services
6777 W. Maple Rd., West Bloomfield, MI 48322
248-661-6484 • Fax 248-661-7370
sscher1@hfhs.org

KEVIN RAND, ATC, CSCS

Kevin is the Detroit Tigers head athletic trainer. Before Detroit, Rand was an assistant athletic trainer with the

Montreal Expos, the Florida Marlins, and the New York Yankees organization. A graduate of Bowdoin College, Rand is the American League head athletic trainer representative of the PBATS Executive Committee and is a certified member of the National Athletic Trainers Association. He lives in Lakeland, Fla. with his wife and four sons.

Kevin Rand, ATC, CSCS
Head Athletic Trainer Detroit Tigers

Steve Carter, ATC
Assistant Athletic Trainer Detroit Tigers

Detroit Tigers, Inc.
Comerica Park
2100 Woodward Avenue, Detroit, MI 48201
313-471-2462

REFERENCE

1. Arnheim DD, Prentice WE. *Principles of Athletic Training*, 8th Edition. St. Louis, MI: Mosby Year Book; 1993: 1-851.
2. Brotzman SB, Wilk KE. *Clinical Orthopaedic Rehabilitation*, 2nd Edition. Philadelphia, PA; 2003:1-652.
3. Attwooll CH, Gil DM, Barckholtz J, Noteboom JT, and Weeks D. In vivo Comparison of Tissue Rise in Two Treatment Area Sizes Using Therapeutic Ultrasound. *JOSPT*. 1995; 27.
4. Draper DO, Sunderland S, Kirkandall, Ricard MD. A Comparison of Temperature Rise in Human Calf Muscles Following Applications of Underwater and Topical Gel Ultrasound. *JOSPT*. 1993; 17(5):247-251.
5. Nyanzi CS, Langridge J, Heyworth JR, Mani R. Randomized Controlled Study of Ultrasound Therapy in the Management of Acute Lateral Ligament Sprains of the Ankle. *Joint. Clin Rehabil*. 1999; 13(1):16-22.
6. Michlovitz S, Smith W, Watkins M. Ice and High Voltage Pulsed Stimulation in Treatment of Acute Lateral Ankle Sprains. *JOSPT*. 1988; 9:301.
7. Bettany JA, Fish DR, Mendel FC, Burton HW. Influence of High Voltage Pulsed Current on Edema Formation Following Impact Injury. *Physical Therapy Journal*. 1990; 70:219-224.
8. Cote DJ, Prentice WE Jr., Hooker DN, Shileds EW. Comparison of Three Treatment Procedures for Minimizing Ankle Sprain Swelling. *Phys Ther* 1988; 68:1072-1076.
9. Linde F, Hvass I, Jurgensen U, Madsen F. Compression Bandage in the Treatment of the Ankle Sprains. A Comparative Prospective Study. *Scand J Rehab Med*. 1984; 16(4):177-9.
10. Vecchio P, Cave M, King V, Adebajo AO, Smith M, Hazleman BL. A Double-Blind Study of the Effectiveness of Low Level Laser Treatment of Rotator Cuff Tendinitis. *Br J Rheumatology*. 1993; 32(8):740-2.
11. Fung DT, Ng GY, Leung MC, Tay DK. Therapeutic Low Level Energy Laser Improves the Mechanical Strength of Repairing Medial Collateral Ligament. *Lasers Surg Med*. 2002; 31:91-96.

CLASS IV LASER THERAPY: EFFECTIVE FOR BACK AND NECK/SHOULDER PAIN

Author: L.D. Morries, DC, CCSP®

CLASS IV LASER THERAPY CASE REPORT

BACKGROUND:

Class IV laser therapy is a recent modality that is used to treat pain and promote healing of muscular tissue. The procedure is minimally invasive and easily performed. Laser therapy was added to conventional chiropractic treatment of spinal manipulation and an exercise program for treating patients with back pain. The objective of this investigation was to assess efficacy and safety of the combination and generate preliminary results for a randomized controlled trial.

METHODS:

Between 9/2009 and 2/2010, a total of 55 patients with non surgical lower back pain (sciatica) presented to my office and gave consent for treatment. Twenty-four patients with back pain received spinal Class IV laser therapy in addition to manipulation for back pain. Twenty-one patients (historical controls) received spinal manipulation without Class IV laser therapy. All patients completed VAS scales before treatment (VAS0), at one week (VAS1), and at four weeks (VAS4). Regardless of treatment group, all patients received a personalized regimen of spinal manipulation, manual therapy, and exercise, under the direction of the principal investigator (LDM). Percent difference between VAS0 and VAS4 was compared between groups.

RESULTS:

Demographics were similar for both groups (Table 1). Patients in the manipulation + laser group reported pain relief after 2-3 sessions of laser therapy (clinical observation). No adverse events were noted following laser therapy

Table 1 – Patient demographics and dependent variables

	N	Age	VAS 0	VAS 4 %	Difference
Laser + Manipulation	24	54.2 ± 11.1	6.5 ± 1.9	1.75 ± 1.6	71.7 ± 22.0
Manipulation Only	21	51.0 ± 12.7	5.5 ± 1.4	3.5 ± 2.1	50.5 ± 28.4

A positive-valued percent differences of VAS between pretreatment and 4wk points; indicate that a quantitative reduction in pain by both treatment groups. Statistical comparison of the groups using an unpaired t-test indicated that the manipulation + laser offers greater pain reduction when compared to manipulation only ($p=0.007$). Interval estimates indicate a 21.18 larger reduction in VAS (95% Confidence Interval: 6.00, 36.35) in the manipulation + laser group.

CONCLUSIONS:

These results indicate that both treatments successfully reduced the VAS by the fourth week of treatment, and that a higher reduction in VAS occurred in the group treated by manipulation + laser at week four.

In summary, Class IV laser therapy is a safe and effective modality for treating low back pain when added to conventional treatment of manipulation and exercise. Further study is indicated to support these initial findings.

ABOUT THE AUTHOR

Dr. Morries was educated at Harvard Medical School – Postgraduate studies in Neurodiagnosis and the American Academy of Neurology on two different occasions for classes in Neurodiagnosis.

His continuing education has included Board Certification in: Neurology, Sports Injuries, Rehabilitation, and Disability Analyst. He attended Classes in Rehabilitation at the #1 Chicago Institute of Rehabilitation.

He is chairman of the Colorado Chiropractic Journal Club; with which he has co-authored papers on; Hip Dysplasia, Carpal Tunnel Syndrome, Thoracic Outlet Syndrome, Plantar Fasciitis, and a case study on Lumbar Osteomyelitis. He was co-author in a Chronic Neck Pain study with Colorado University Health Science Center study and currently involved a co-author, in a second study with CU on Lumbar Spine Pain and Laser Therapy.

CLASS IV LASER THERAPY TREATMENT OF MULTIFACTORIAL LUMBAR STENOSIS WITH LOW BACK AND LEG PAIN

Author: Daniel Knapp, DC

CLASS IV LASER THERAPY CASE REPORT

INTRODUCTION:

Lumbar stenosis is present when neural elements are compromised in the central canal, lateral recess, and/or neural foramen. The prevalence of lumbar stenosis in the general population predilection is 1.7% to 8%; the condition usually develops in the 5th to 6th decades of life. This is typically due to degenerative changes of the disc, bulges, herniations, hypertrophic facets, ligamentum flavum overgrowth or buckling, and/or spondylolisthesis. Other complicating factors can include scoliosis, kyphosis, infection, or pathological spaceoccupying lesions. The impairment of the nerve roots and cord is more common from decreased cerebrospinal fluid (CSF) flow, which is responsible for 60% of nutrition to these structures, not frank compression.

KEY INDEXING TERMS:

Laser therapy, low-back pain, intervertebral disc displacement, spinal stenosis

OBJECTIVE:

This case report is presented to offer a potential intervention strategy in the treatment of resistant chronic back and leg pain with multifactorial central and foraminal stenosis.

CLINICAL FEATURES:

A 77-year-old female with bilateral total knee replacement (TKR) and total hip replacement (THR) presented using a walker for gait assistance and in obvious distress. She reported constant pain levels of 3 to 10 out of 10, with sharp pain across the lower back, buttocks, and posterior hips. The symptoms originally began 9 months prior, following left THR. Five epidural steroid injections failed to significantly reduce pain levels. Oxycodone was minimally effective in reducing her pain. MRI revealed L4-5 grade 1 anterolisthesis, with moderate-to-severe right foramen stenosis, mild central stenosis, and L5-S1 disc protrusion abutting the thecal sac and right S1 nerve root, establishing multiple potential pain generators.

INTERVENTION AND OUTCOME:

Initially, the only modality utilized was the K-laser 10d Class IV therapeutic laser. Dosage was set at 9 to 10 W, continuous wave and pulsed at variable frequencies from 2 to 10,000 Hz, for each 6-to-10-minute treatment session. A 400-to-900-cm² area of the lower lumbar and gluteal

regions received 1,600 to 3,300 J total per treatment for a 1.8 to 8.2 average J/cm². Eleven treatments in a 9-week period resolved pain on the left side and reduced the pain scale report on the right side by 50%. Prone diversified-type manual manipulation of the bilateral SI restriction was performed on the 4th visit. Pre-adjustment pressure along the intended line of drive produced no pain referrals, and no extension of the lumbar spine was permitted. This treatment was reported as aggravating and discontinued at the patient's request. No other interventions were employed, and the patient was asked to increase physical activity as tolerated. Progressive reductions in pain allowed her to be more active, improving range of motion and general conditioning through adding activities of daily living that had been previously intolerable.

CONCLUSION:

Class IV laser therapy may be a treatment option in patients with chronic multifactorial low-back pain, possibly allowing for earlier active intervention and return to ADLs. Natural history influence on improvement cannot be excluded as a contributory factor in symptom reduction in this case study. Since laser therapy was initiated 9 months post-injury with ongoing symptoms, the amount of contribution is uncertain. More controlled studies with high-power laser therapy and significantly greater total doses than are possible with Class II and III lasers are necessary for a broader understanding of this emerging modality.

A complete copy of the Report is available at:
<http://backtowellnessclinic.com/wp-content/uploads/2012/08/LumbarStenosisandLegPain.pdf>

ABOUT THE AUTHOR

Daniel Knapp, DC, has a Private Practice in Sarasota, FL and is also the University of Miami Miller School of Medicine Complementary and Integrative Department laser therapy consultant.

Daniel Knapp, DC
3982 Bee Ridge Rd., Bldg. H/H
Sarasota, FL, 34233
(941)-925-2211
knapplaser@gmail.com

THE IMPORTANCE OF TREATING PATIENTS AND NOT IMAGES IN THE MANAGEMENT OF CHRONIC BACK AND LEG PAIN

Author: Joseph A Costello Jr. DC, DABCO

CLASS IV LASER THERAPY CASE REPORT

HISTORY:

This patient is a 37 year old female from Munich, Germany who has suffered with chronic back and leg pain for over 10 years. She suffers from leg pain which extends into the foot, more so on the left. She has been treated with many forms of conservative care including physiotherapy, pain medication, and epidural steroid injections, all without relief. She was contemplating surgical intervention prior to presenting for high power laser therapy (HPLT).

CLINICAL EXAMINATION:

NEUROLOGICAL EXAM:

DTR 2-/2 and symmetrical at the patella, achilles reflexes are 2/2 and symmetrical. All myotomes including EHL's are 5/5. Circumferential mensuration of the legs and calves were symmetrical and negative for long standing atrophy. Sensation to pinprick was intact. Babinski sign was flexor. She was able to heel and toe walk without difficulty.

ORTHOPEDIC EXAMINATION:

Straight leg raising was 90 degrees and negative for root tension signs. There was exquisite tenderness in the left Sciatic notch. There was also significant tenderness in the left sacroiliac joint at the superior pole. There was focal tenderness over the spinous process at L5. Flexion/extension provocation testing revealed complete centralization of pain from the lower extremity as well as the left Sciatic notch with hyperextension of the lumbar spine. Flexion precipitated radiation into the left lower extremity. Sitting SLR with neck flexion and Valsalva's maneuver revealed increased pain in the left leg below the knee. Orthokinetic evaluation of the weight bearing patient revealed bilateral subtalar pronation with mild inferiority of the right hemi-pelvis. There was only minimal tenderness in the periarticular myofascial tissues of the hip joints bilaterally.

IMAGING/ MRI:

T1 & T2 weighted images in the sagittal and transaxial planes were reviewed. There was disc desiccation at L3/4, L4/5, and L5/S1. There was a small disc protrusion at L3/4 with effacement of the thecal sac. There was also disc bulge at L4/5. Most interesting was a High intensity zone in the posterior annulus.

DIAGNOSIS:

Chronic left lumbosacral radiculopathy. Degenerative disc disease with L3/4 disc protrusion and "hiz" formation. Right sided kinetic chain dysfunction.

TREATMENT PLAN:

This patient was immediately cast in talar neutral for

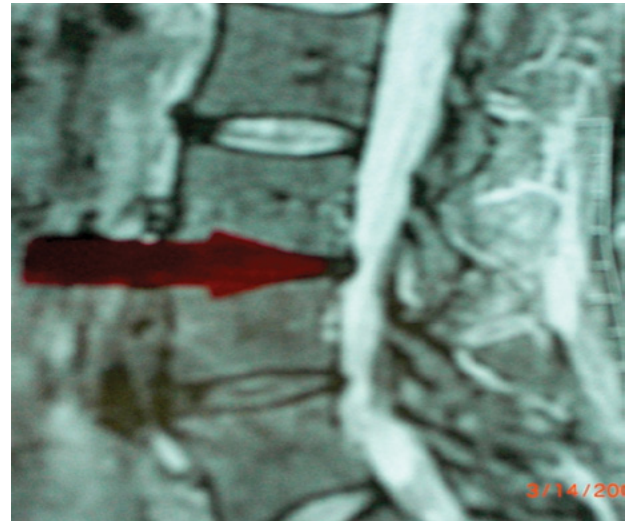


IMAGE 1 — IMAGING/MRI

custom fabricated orthotics to correct her kinetic chain dysfunction.

She began a trial with a right sided 5mm heel lift. She was placed in hyperextension. Once again, there was complete centralization of left sided leg pain as well as tenderness to the left Sciatic notch. She was treated with the high power laser beginning at 6 watts for 10 minutes to the lumbar spine and 10 minutes to the left Sciatic notch. The dosage was increased each visit until she was treated at 12 watts of power for 10 minutes to the lumbar spine and 10 minutes to the left Sciatic notch. She was treated for a total of 11 treatment sessions. Her results were quite remarkable are described by the patient in a video testimonial at the end of her treatment plan just prior to her returning to Germany.

DISCUSSION:

Laser therapy is classified as an actinotherapy which results in biostimulation of the chromophores inside the mitochondria of each cell^{1,8}. This photo-stimulation results in increased cellular metabolism, vasodilatation, and neo-capillary growth within the outer 1/3 of the annulus⁹. Although the High Power Laser is warm, the results are photochemical and not thermal⁸. Biostimulation translates into reduction of inflammation and increased lymphatic drainage.^{5,6}

Regarding patients suffering from back and leg pain, the High Power Laser is thought to decrease inflammation of the disc pathology and nerve root as well as aid in nerve repair and regeneration. In order to achieve optimal healing and long term results, it has been found in a clinical setting that all biomechanical abnormal forces need to be removed so healing is not interrupted or compromised during gait, thus the need for orthotic correction is paramount in case

management of the patient with long term back and leg complaints. This is proven by the facts of this case which reflect chronic long standing back and leg pain of 10 years duration which was refractive to all forms of traditional case management and then astoundingly was resolved within a 2 week period, with orthotic gait correction and high power laser therapy.

SUMMARY:

High Power Laser Therapy has the ability to reach deep within the body when compared to Low Level Laser Therapy⁸. When used in a patient whose biomechanical abnormalities have been corrected, the results achieved seem to be long term in nature especially when compared to all other forms of traditional and alternative care. This may also be due to the fact that laser energy appears to also bio-stimulate collagen and fibroblast growth which would enhance the tensile strength of the annular fibers of the degenerative disc patient^{1,2,3,4}.

ABOUT THE AUTHOR

Dr. Costello is a Board certified chiropractic orthopedist. He is also Board certified in quality assurance and utilization review, and has been practicing continuously in Palm Beach County for 26 years. Dr. Costello was formerly the president Florida College of Chiropractic Orthopedist (1993 to 2005), and also the chief of clinical services Avicenna Laser Technology (April 2006 through September 2011). He is a published author and lecturer on Class IV laser therapy and clinical practice.

REFERENCES:

1. Effects of infrared laser exposure in a cellular model of wound healing. Skopin M and Molitor S, Dept. of Bioengineering, University of Toledo, Toledo OH.
2. Mester E, Mester AF, Mester A (1985) The Biomedical effects of laser application. *Lasers Surg. Med.* 5:31-39.
3. The influence of low level infra red laser therapy on the regeneration of cartilage tissue. P Lievens, Ph. Van der Veen.
4. Therapeutic low energy laser improves the mechanical strength of repairing medial collateral ligament. Fung DT, Ng GY, Leung MC, Tay DK, *Lasers Surg Med.* 2002; 31: 91-96.
5. Double-blind randomized study evaluating regeneration of the rat transected sciatic nerve after suturing and postoperative low-power laser treatment. *Journal of Reconstructive Microsurgery.* 2001; 17 (2): 133-137. Shamir MH, Rochkind S, Sandbank J, Alon M.
6. Effects of laser irradiation on the spinal cord for the regeneration of crushed peripheral nerve in rats. *Lasers in Surgery and Medicine* 2001, 28(3): 216-219. Rochkind S, Nissan M, Alon M et al.
7. Assessment of laser therapy for late postoperative pain after lumbar fusion surgery and for pain and wound healing after acute traumatic injury – preliminary results. Biyani A, Skie M, Goel V, Ciocanel D, University of Toledo School of Medicine.
8. Class IV “High Power” laser therapy in Chiropractic and rehabilitation. Wertz R., *Dynamic Chiropractic* 2006 vol. 24, issue 23.
9. Vascularization of the intervertebral disc in pathological conditions. Moore R, University of Adelaide, Feb. 1995.

TREATMENT OF AN ACUTE DISC HERNIATION RESULTING IN RADICULOPATHY AND FOOT DROP USING HIGH POWER LASER THERAPY

Author: Joseph A. Costello Jr. DC, DABCO

CLASS IV LASER THERAPY CASE REPORT

OBJECTIVE:

To demonstrate the efficacy of High Power Laser Therapy as a treatment solution for a patient with an acute disc herniation non-responsive to traditional medical treatments.

HISTORY:

This patient is an adult male who injured his low back during a golf outing two months prior. His initial complaints included low back pain with radiation into his left lower extremity. At the time of presentation, he rated his pain as a ten on a visual analog pain scale. At the time of presentation, he had already completed several epidural steroid injections without relief.

CLINICAL EXAMINATION:

Height: 6'6" Weight: 260 lbs.

NEUROLOGICAL EXAMINATION:

DTR: 2/2 and symmetrical. Dermatomal sensation was intact. Myotomal evaluation revealed 4+/5 weakness to the left anterior tibialis muscle. Long tract signs show no beats of ankle clonus. Babinski's sign was flexor. Heel and toe walking revealed foot drop weakness/ fatigue to the left anterior tibialis.

ORTHOPEDIC EXAMINATION:

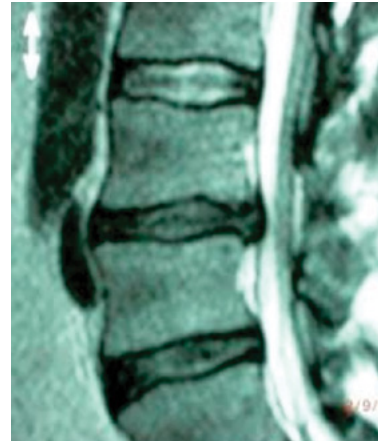SLR was 25 degrees left and 35 degrees right with classic root tension signs on the left. The sciatic notch was exquisitely tender on the left side. Springing maneuvers showed pain over the spinous processes at L3 and L4. Sitting Bechterew's performed with neck flexion and Valsalva's maneuver revealed leg pain into the left foot and toes. Femoral nerve stretch test did not reveal L4 root tension signs.

RADIOGRAPHIC FINDINGS:

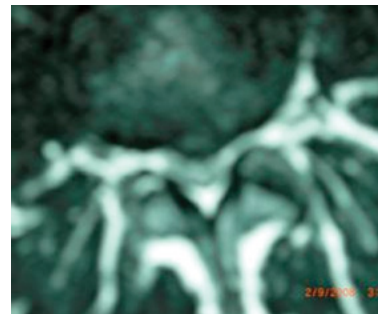
MRI evaluation of the Lumbar spine was reviewed. This study consisted of both T1 and T2 weighted images in the sagittal and transaxial planes. There was a moderate central disc herniation at L3/4. Mild eccentric stenosis of the left IVF was also present (see pre treatment images).

TREATMENT PLAN (METHODS) AND RESULTS:

The patient underwent flexion/extension provocation testing. Complete centralization from his left lower extremity was achieved in neutral hyperextension of the lumbar spine. He was then treated in this static position with High Power Laser Therapy (5.0-7.5 watts for 10 minutes) to each of the following: L3/4 disc space, left sciatic notch, and left posterior tibial/ common peroneal

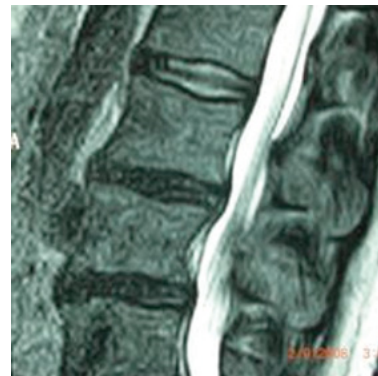


Pre-treatment T2 weighted sagittal Pre-Treatment T2 weighted axial

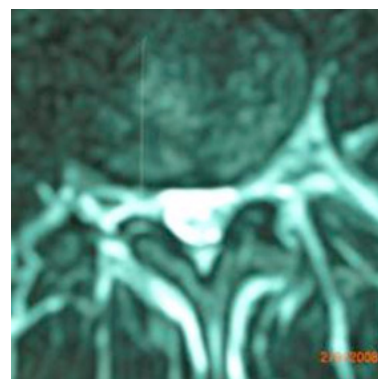


Pre treatment T2 weighted axial L3/4

POST TREATMENT RADIOGRAPHIC FINDINGS:



Post treatment T2 weighted sagittal



Post treatment T2 weighted axial L3/4

Treatment	Wattage	Time (minutes)	Dosage-Joules	Treatment Notes
1	5.0	30	9,000	Left sciatic notch tenderness. Extension centralizes radiation to leg. Left Ant. Tibialis 5-/5.
2	6.0	30	10,800	Midline tenderness L3 & L4. Tenderness left sciatic notch & fibular head (common peroneal nerve).
3	7.5	30	13,500	Patient reports decreased severity of radiating pain into left lower leg. Heel walking is 5-/5.
4	7.5	30	13,500	Left leg pain continues to decrease. Extension decreases tenderness in left sciatic notch.
5	7.5	30	13,500	Tenderness is decreased over L3 & L4 as well as fibular head (common peroneal nerve).
6	7.5	30	13,500	Only low grade aching remains over fibular head. Anterior tibialis is 5-/5 on left.
7	7.5	30	13,500	No midline tenderness (L3 & L4). The left sciatic notch is also non tender.
8	7.5	30	13,500	Improvement with heel/ toe walking. Anterior tibialis is 5/5 (non weight bearing).
9	7.5	30	13,500	No low back pain or sciatic notch tenderness. No aching in left lower leg.
10	7.5	30	13,500	Heel/toe walking is 5/5. No root tension signs. No radiation into left lower leg.

Table 1 – Summary of 10 Treatment Sessions

nerve, total dosage of 9,000-13,500 Joules per session. This patient received a total of ten treatment sessions with the high power laser. At the end of the treatment plan, he was asymptomatic with normal neurological and orthopedic findings. His foot drop had also resolved completely. (See Table1)

CONCLUSION:

High Power Laser Therapy has the ability to penetrate deeply and “bio stimulate” tissue to heal. Laser photonic stimulation has been shown to increase blood flow and lymphatic drainage while at the same time stimulating endorphin and enkephalin release for pain management⁸. Biostimulation translates into reduction of inflammation, and nerve regeneration^{5,6}. Regarding patients suffering from back and leg pain, the High Power Laser is thought to decrease inflammation of the disc and nerve root as well as aid in nerve regeneration⁵. Healing of annular defects in the outer 1/3 of the disc (which is vascularized) have the ability to heal⁹. Of interest in this particular case study is the fact that this patient has been followed for over 18 months. During that timeframe, he has not experienced any exacerbations of back or leg pain and has returned to all previous activities without pain!

High Power Laser Therapy also has the ability to reach deep within the body when compared to Low Level Laser Therapy⁸. Results achieved seem to be long term in nature when compared to all other forms of treatment for disc pathologies. This may also be due to the fact that laser energy appears to also biostimulate collagen and fibroblast growth which would enhance the tensile strength of the annular fibers of the degenerative disc patient^{1,2,3,4}. Clearly, further investigation regarding a large scale blinded study is necessary to further correlate patient’s clinical findings with pre and post imaging studies.

ABOUT THE AUTHOR

Dr. Costello is a Board certified chiropractic orthopedist. He is also Board certified in quality assurance and utilization review, and has been practicing continuously in Palm Beach County for 26 years. Dr. Costello was formerly the president Florida College of Chiropractic Orthopedist (1993 to 2005), and also the chief of clinical services Avicenna Laser Technology (April 2006 through September 2011). He is a published author and lecturer on Class IV laser therapy and clinical practice.

REFERENCES:

1. Effects of infrared laser exposure in a cellular model of wound healing. Skopin M and Molitor S, Dept. of Bioengineering, University of toledo, Toledo OH.
2. Mester E, Mester AF, Mester A (1985) The Biomedical effects of laser application. *Lasers Surg. Med.* 5:31-39.
3. The influence of low level infra red laser therapy on the regeneration of cartilage tissue. P Lievens, Ph. Van der Veen.
4. Therapeutic low energy laser improves the mechanical strength of repairing medial collateral ligament. Fung DT, Ng GY, Leung MC, Tay DK, *Lasers Surg Med.* 2002; 31: 91-96.
5. Double-blind randomized study evaluating regeneration of the rat transected sciatic nerve after suturing and postoperative low-power laser treatment. *Journal of Reconstructive Microsurgery.* 2001; 17 (2): 133-137. Shamir MH, Rochkind S, Sandbank J, Alon M.
6. Effects of laser irradiation on the spinal cord for the regeneration of crushed peripheral nerve in rats. *Lasers in Surgery and Medicine* 2001, 28(3): 216-219. Rochkind S, Nissan M, Alon M et al.
7. Assessment of laser therapy for late postoperative pain after lumbar fusion surgery and for pain and wound healing after acute traumatic injury – preliminary results. Biyani A, Skie M, Goel V, Ciocanel D, University of Toledo School of Medicine.
8. Class IV “High Power” laser therapy in Chiropractic and rehabilitation. Wertz R., *Dynamic Chiropractic* 2006 vol. 24, issue 23.
9. Vascularization of the intervertebral disc in pathological conditions. Moore R, University of Adelaide, Feb. 1995.

EFFECTS OF CLASS IV LASER THERAPY ON DISEASE IMPACT AND FUNCTION IN WOMEN WITH FIBROMYALGIA

CLASS IV LASER THERAPY CASE REPORT

Authors: Kristen Williams, Reed Mathis, J. Derek Kingsley, Emily Simonavice, Francesca Charles, Chris Mojock, Jeong-Su Kim, Victor McMillan, Lynn Panton, FACSM.

Florida State University, Tallahassee, FL

ABSTRACT

OBJECTIVES:

This study evaluated the effects of Class IV laser therapy on pain, Fibromyalgia (FM) impact, and physical function in women diagnosed with FM.

DESIGN:

The study was a double-blind, randomized control trial.

SETTING:

Testing was completed at the university and Rheumatologist office and treatment was completed at a chiropractic clinic.

PARTICIPANTS:

Thirty-eight (38) women (52±11 years; mean±standard deviation) with FM were randomly assigned to one of two treatment groups, laser heat therapy (LHT; n=20) or sham heat therapy (SHT; n=18).

INTERVENTION:

Both groups received treatment twice a week for 4 weeks. Treatment consisted of application of LHT or SHT over seven tender points located across the neck, shoulders, and back. Treatment was blinded to women and was administered by a chiropractic physician for 7 minutes.

OUTCOME MEASURES:

Participants were evaluated before and after treatment for number and sensitivity of tender points, completed the FM Impact Questionnaire (FIQ) and the pain question of the FIQ, and were measured for function using the continuous scale physical functional performance (CS-PFP) test. Data were evaluated using repeated-measures analysis of variance with significance accepted at $p \leq 0.05$.

RESULTS:

There were significant interactions for pain measured by the FIQ (LHT: 7.1±2.3 to 6.2±2.1 units; SHT: 5.8±1.3 to 6.1±1.4 units) and for upper body flexibility measured by the CS-PFP (LHT: 71±17 to 78±12 units; SHT: 77±12 to 77±11 units) with the LHT improving significantly compared to SHT. There was a time effect for the measure of FM impact measured by the FIQ, indicating that FM impact significantly improved from pre- to post-treatment in LHT (63±20 to 57±18 units), while no change was observed in the SHT (57±11 to 55±12 units).

CONCLUSIONS:

This study provides evidence that LHT may be a beneficial modality for women with FM in order to improve pain and upper body range of motion, ultimately reducing the impact of FM.

ABOUT THE AUTHORS

Lynn Panton, PhD,¹ Emily Simonavice, PhD,² Kristen Williams, MS,¹ Christopher Mojock, MS,¹ Jeong-Su Kim, PhD,¹ J. Derek Kingsley, PhD,³ Victor McMillan, MD,⁴ and Reed Mathis, DC⁵

¹Department of Nutrition, Food and Exercise Sciences, The Florida State University, Tallahassee, FL.

²Georgia College and State University, Milledgeville, GA.

³Indiana State University, Terre Haute, IN.

⁴McIntosh Clinic, Thomasville, GA.

⁵Mathis Chiropractic, Tallahassee, FL.

Address correspondence to:

Lynn B. Panton, PhD, FACSM

Department of Nutrition, Food & Exercise Sciences
436 Sandels Building
The Florida State University
Tallahassee, FL 32306

E-mail: lpanton@fsu.edu

CERVICOGENIC OR VERTEBROGENIC HEADACHES

Author: Jerome True, DC

CLASS IV LASER THERAPY CASE REPORT

Headaches that rapidly resolve following chiropractic treatment should empirically be classified as vertebrogenic or cervicogenic. One would think that headaches originating from the cervical spine would all be termed a “cervicogenic headache” however, cervicogenic headaches have criteria that limits its use for diagnosis. (This criteria really should be changed to reflect current scientific understanding and variability of the cervicogenic category).

The classic definition of cervicogenic headache was originally proposed by Sjaastad in 1983. It has 3 criteria (1) unilateral headache triggered by head/neck movements or posture; (2) unilateral headache triggered by pressure on the neck; (3) unilateral headache spreading to the neck and the homolateral shoulder/arm. This classification of headache is still not accepted by The International Headache Society (IHC). Rather than recognizing this obvious form of headache, the IHC labels these headaches as a subset etiology of the tension-type headache or a variant of chronic daily headaches (CDH). The post traumatic patient may be diagnosed with new daily persistent headache (NDPH) a recent classification for headaches having multiple etiologies such as headache from post-concussion, subarachnoid hemorrhage, recent infection or other relatively rare disorders.

The cervicogenic headache is one of the few types of headache where the source of pain originating from the reflexive pain generators in the spine can clearly and convincingly be identified based on segmental localization. Although the provocative cause of many headaches may be evident such as lumbar puncture headache, meningitis headache, toxic triggers or post concussion headache, the mechanism of pain production in most headaches is still incompletely understood or completely unknown.

An alternative name for headaches originating from the spine is “vertebrogenic headache”. This term was proposed by Howard Vernon, D.C. a researcher and professor from Canadian Memorial Chiropractic College to avoid the limitation created by the overly narrow definition created by Sjaastad for cervicogenic headache.

CASE STUDY 1

Post traumatic 33 year old male patient with intensifying HA and nausea, disc herniations present at C3-4, C6-7 and T1-2. Normal brain MRI. Increased HA on cervical flexion. HA behind eyes, base of skull and vertex. Unrelenting HA for 3 months since MVA, unresponsive to Vicoden or Lortab. Multiple physicians consulted before referral to my office. Confirmation of spinal generators using manual axial traction applied to C6-7 on the left. Simultaneous axial decompression of C3-4 and suboccipital C1 level. HA reduction for 20-30 seconds with this maneuver. Treatment: Class IV laser to capsular region and intrinsic trigger points in the cervical spine. Results: Near complete resolution on first visit.

CASE STUDY 2

Post traumatic 57 year old female patient with significant cervical DJD and multiple broad based HNPs. HA for 6 months duration since MVA, patient was taking aspirin or Tylenol on a daily basis. A mild C7 radiculopathy was also present with variable intensity reported between visits. Her HA was the primary complaint. She had regular chiropractic care for 6 months without any reduction in HA intensity. Class IV was used in the suboccipital and posterior cervical intrinsic musculature as well as scapular elevator musculature. There was no change in the patient’s symptoms following the first two treatments. Following the third laser treatment, the patient had complete resolution of HA symptoms. On a follow-up visit five months later, there were no episodes of HA reported.

ABOUT THE AUTHOR

Jerry True, D.C., FIACN is a chiropractic neurologist in private practice and has over 25 years of practice experience in functional neurology, clinical nutrition, and wellness care. He has lectured throughout United States on the topics of laser therapy and neurology for multiple continuing education venues. Dr. True is the co-author of the textbook on neurology titled *Myelopathy, Radiculopathy and Peripheral Entrapment Syndromes*, and has contributed book chapters and illustrations to textbooks on sports medicine, neurology and soft tissue medicine. He has also contributed to research and published articles on laser therapy.

NECK PAIN DYNAMICALLY INDUCED CHRONIC CORD COMPRESSION AND RADICULOPATHY

Author: Jerome True, DC

CLASS IV LASER THERAPY CASE REPORT

Confirming the source neurological compression in the patient with intermittent dynamically induced symptoms may be a diagnostic challenge. This diagnostic challenge is compounded when the doctor relies on a static x-ray or MRI report that discounts small structural intrusions in the spinal canal as being clinically insignificant.

Symptoms that manifest during movement may be difficult to image if the mass-effect is small or provoked at end range motion. The following case is interesting because of the obvious change in pathologic interpretation between flexion and neutral positioning.

The neutral lateral MRI (read by another radiologist) was considered to only have disc bulges. However, the purpose of this case study review is not to urge doctors to order flexion MRIs as standard practice. It is a reminder that the spine is a dynamic structure and intermittent symptomatic compression of the neural elements may not be apparent on a static film. Thus, treatment may be delayed and the potential for chronicity may be underestimated.

Greater deviation of neural elements or larger deformation has a greater potential to produce symptoms. Deformation of the spinal cord or square area of the spinal cord can be clinically graded however most radiologists do not use a measurable scale. Nagata et al¹ described a useful four-level scale based on T1 weighted sagittal images of the cervical spine. The spinal cord may also be deviated without obvious compression, causing excessive traction on the cord or roots. The degree of compression and intensity of symptoms may not be in direct proportion in cases of mild compression with extensive inflammation.

CLINICAL HISTORY:

43 y/o male with history of neck and upper quarter repetitive injury during full contact martial arts sparring. His pain was described as intense in the supraclavicular fossa and suprascapular region on the right. He had multiple epidural injections and a C6 sensory root rhizotomy. The patient had short-term benefits from these invasive procedures without complete resolution of his pain. He was unable to work in full capacity and upper extremity exercises intensified his radicular symptoms. Scalene and omohyoid muscular injury was suspected in addition to disk herniations observed on MRI. Chiropractic treatment over the three years after injury provided reduction in pain however periods of severe break-through pain occurred with activity.

LASER TREATMENT PROTOCOL:

Class IV laser was used in the following regions and protocol:

- The posterior and lateral articular pillars C4-C7 and paravertebral muscles were treated in the cervical spine.
- The upper thoracic spine T1-T4 and right paravertebrals were treated predominantly in the thoracic spine.

- Trigger points in the ascending trapezius, omohyoid, scalene groups on the right were treated in conjunction with stretching.
- The treatment protocol used a dual infrared beam laser in the 800 nm and 970 nm ranges set at 3W of power for a duration of 15 minutes in the areas listed above. The initial treatment program was 1-2 visits per week over two months.
- There were three treatment phases during each session consisting of the frequencies 2 Hz, 10 Hz and 500 Hz. The probe was moved from point to point with direct contact technique in a grid pattern approximately 4-6 seconds per point.

RESULTS OF TREATMENT:

The patient had significant relief of pain after the first visit. By the third visit, his pain had dramatically reduced to a tolerable level. His need for pain medication also was reduced. At the end of the second month, he no longer needed narcotic pain meds and was sleeping much better.

He was still unable to return to pre-injury sports activities or work level, however he reported days without radicular pain and only mild pain on light activity. This improvement status has continued for six months with the patient only requiring treatment on a weekly basis. The intractable pain returned on a few occasions following physical activity.

The treatment was considered highly successful because prior to the intervention with Class IV laser, the patient was taking Vicoden on a daily basis and had constant nagging intractable pain shooting into his supraclavicular fossa. His quality of life had improved and the patient was making it through the day without the need for narcotic pain relievers. Spinal cord compression noted at the C5-6 level and the T2-3 level with cervical flexion. These disk herniations were only part of the mechanisms responsible for pain production in this patient. Injury to the scalenes and omohyoid muscles was clinically suspected.

ABOUT THE AUTHOR

Jerry True, D.C., FIACN is a chiropractic neurologist in private practice and has over 25 years of practice experience in functional neurology, clinical nutrition, and wellness care. He has lectured throughout United States on the topics of laser therapy and neurology for multiple continuing education venues. Dr. True is the co-author of the textbook on neurology titled *Myelopathy, Radiculopathy and Peripheral Entrapment Syndromes*, and has contributed book chapters and illustrations to textbooks on sports medicine, neurology and soft tissue medicine. He has also contributed to research and published articles on laser therapy.

REFERENCE

1. Nagata, K et al. Clinical use of magnetic resonance imaging for cervical myelopathy. *Spine*. 15(1):1088-1096,1990.

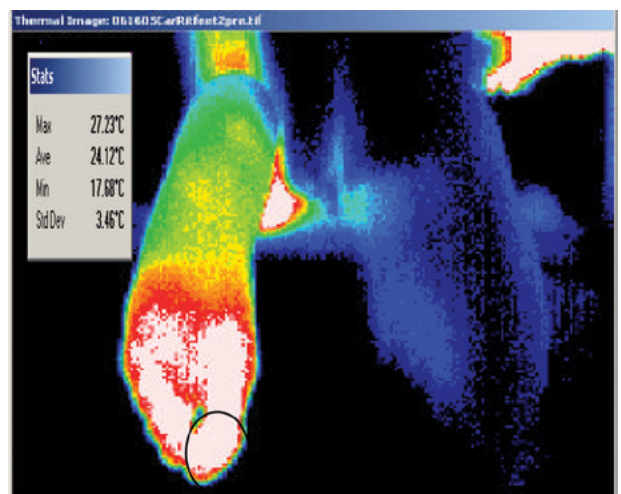
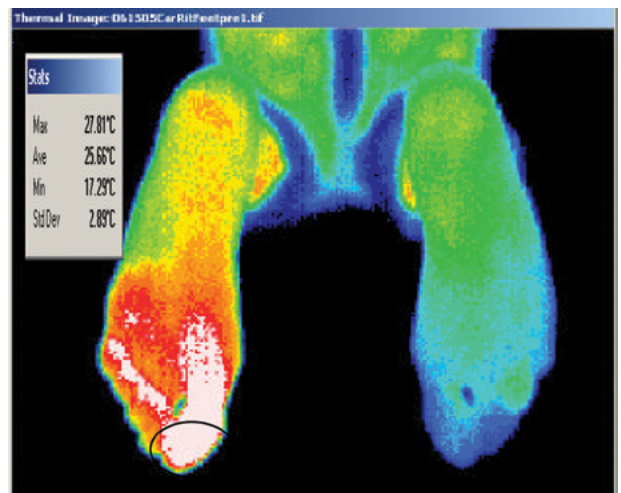
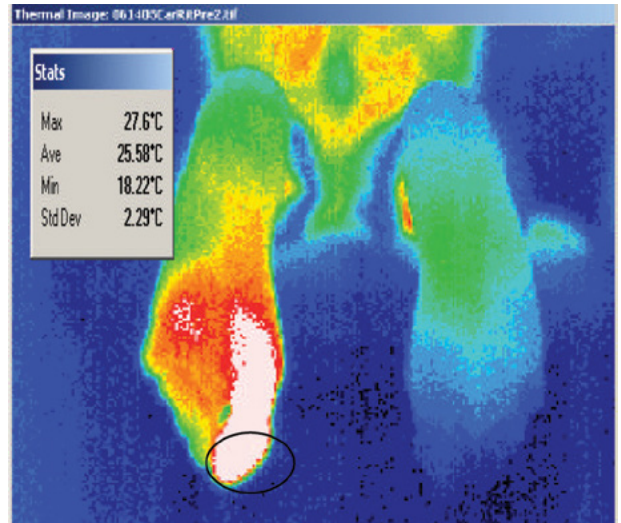

POLYNEUROPATHY TREATED WITH CLASS IV THERAPY LASER

Authors: Craig A. Mueller, DC, CACBII, Jerry Koziej, DC, CSP

CLASS IV LASER THERAPY CASE REPORT

High resolution Digital Infrared Thermal Imaging reveals radiation emission patterns emitted by the microcirculation in the skin. The sympathetic nervous system ultimately controls this function though it is influenced by central and local stimuli as well. The image above is the plantar surface of the feet of a 52 year old female. Her medical diagnosis upon presentation was small fiber sensory polyneuropathy. Her symptoms began in November 1998 and did not involve a specific injury. She recalled the burning sensations originating in both feet one year after she began taking Statin drugs. Additionally, she was walking approximately 90 minutes per day on a treadmill to combat elevated cholesterol levels. She reported the muscular spasms in her legs to her prescribing doctor and her meds were changed to various Statins before being suspended in January 2000. The May 14, 2002 edition of American Journal of Neurology published the results of a Danish study claiming that people taking Statin drugs were 14 times more likely to develop a peripheral neuropathy than those not taking the drug. Subjects in the Danish study took Statins for an average of 2.8 years. In this case, discontinuing the Statin drugs did not reverse her condition; her pain progressed. One year into her Satin treatment burning pain dominated her feet. A year later her feet and ankles began to swell. As the condition progressed, she described her pain as “standing in scalding water.” When the image above was made, the skin tone on each foot was purple. The thermographic significance in this image is the localized hyperthermic pattern over the proximal interphalangeal joint on the left foot.

This case illustrates how advances in this technology assist the doctor in arriving at a proper diagnosis, localizing treatment and monitoring response to care. These images are intended to show the rapid and demonstrable impact a Class IV therapeutic laser had on vasomotor stability resulting in a dramatic reduction in pain and disability.



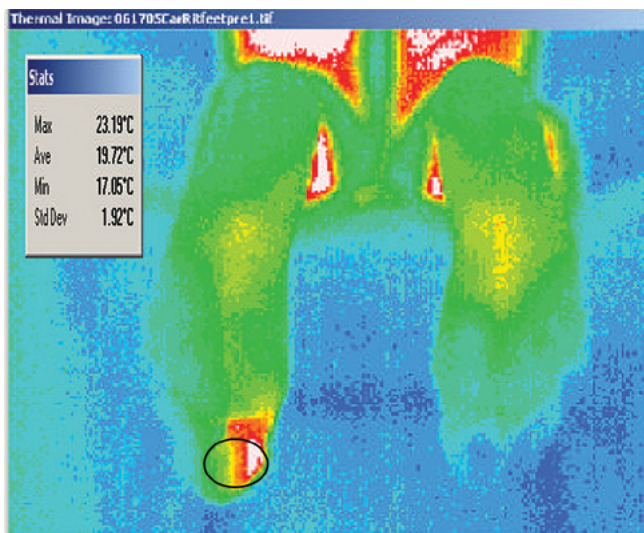
The images to the above were recorded before Class IV laser treatment began on days two, three and four respectively. Each session lasted fifteen minutes, involved a continuous 7.5 watt output through a 7 cm/diameter beam and a 980nm bandwidth. A 7.3 degree difference is recorded between the toe great toes.

Treatment to the right foot was decided on for many reasons. First, although the most remarkable finding was on the left foot, there was no indication a localized injured had occurred at that level. Second, the patient could not recall pain specifically emanating from that location. The history indicated the condition began following another chemical insult to the peripheral nervous system resulting in hypersensitization or Cannon's phenomenon. Theoretically this predisposed the nerves at the PIP joint on the left great toe to mechanical insult during ordinary locomotion, as the patient described, resulting in an emerging "Angry Backfiring C fiber" as described by Ochoa. Additional consideration in selecting the right foot was given to the depth the Class IV laser could penetrate as well as the high wattage photochemical sensory input to the peripheral afferent pathways and the observable efferent response in the left foot. Finally, for practical purposes, treatment to the right foot would serve as a control measure in the event the desired outcome was not achieved and subsequent treatment was applied to the PIP on the left great toe.

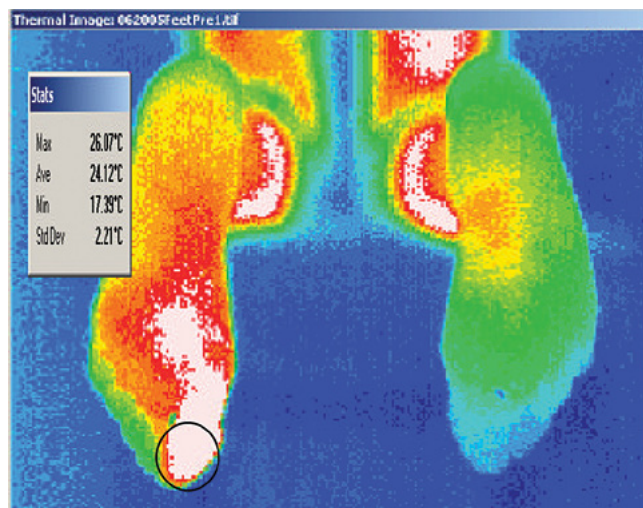
While the right foot warmed slightly, the left PIP expanded beyond the original borders and followed the vascular course across the foot surface. The beam to the right foot was applied in a slow, sweeping, "paintbrush" fashion. Laser treatment was limited to the right foot only for the first five days.

Visible reaction confirms the afferent/efferent sympathetic pathways do receive and transmit information. The patient tolerated all therapy without any adverse consequence. By the third day, the right foot is showing improved vasomotor stability and a more normal skin tone is observed on both feet.

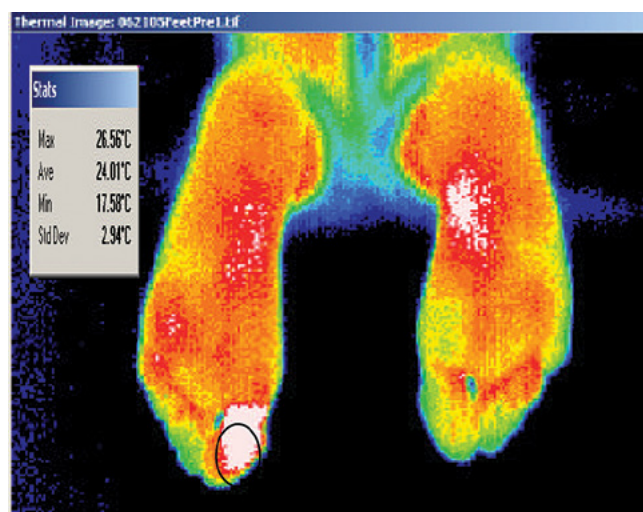
The bottom view shows the persistent dilation in the left great toe and plantar surface and the right foot is now reacting to the ambient cold temperature. Objective visible stability is not confirmed in spite of the patient's encouraging subjective remarks.



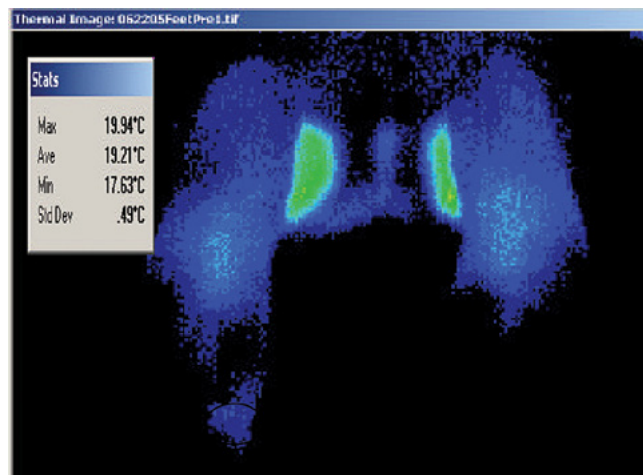
The top view reveals the plantar surface following four consecutive daily Class IV laser applications. The thermal balance between the two feet, save the remaining focal hyperthermia on the left PIP, is impressive given that all treatment was applied to the right foot.



This view was taken four days later. The patient felt so well she went shopping for two hours; the first time in many years. Afterwards the burning came back in the feet with a vengeance. Following this scan, treatment was directed to the left foot for the first time.

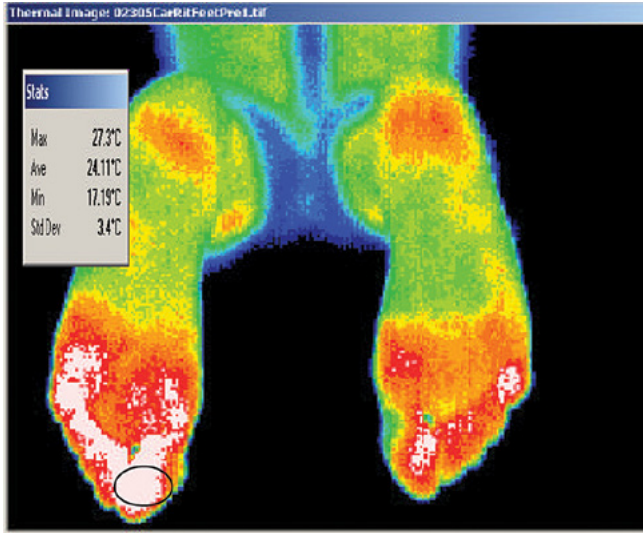


This image represents one day post left foot laser therapy. The first laser treatment to the left PIP on the great toe yielded the most remarkable subjective response by the patient. The temperature differential between the two great toes is 2.3 degrees C.

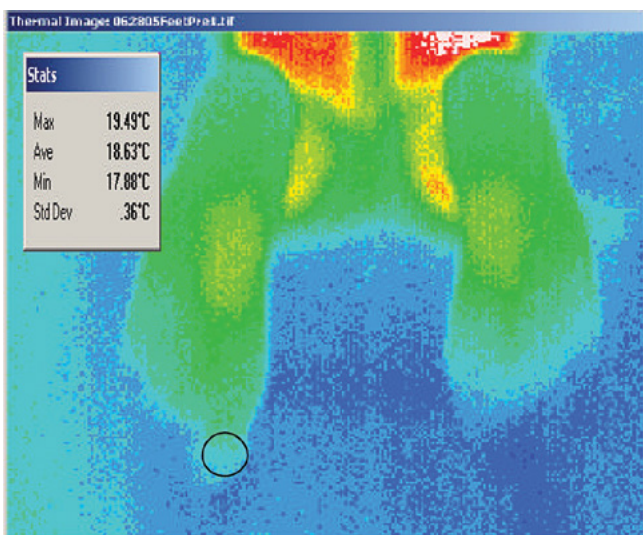


This image is before the third treatment to the left PIP in the great toe. Her feet at rest look perfectly normal, the best they have in years, and her pain level is dramatically

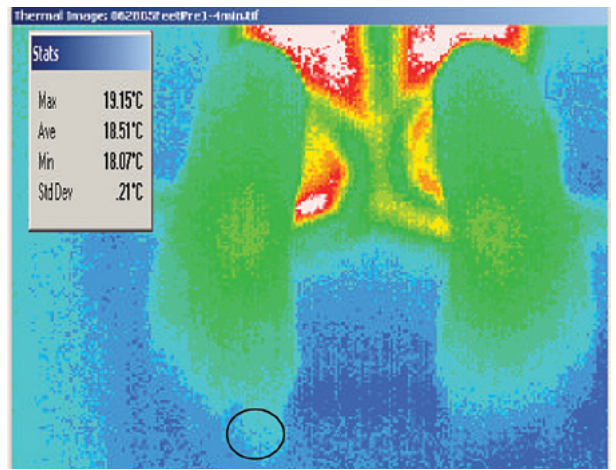
reduced. She can now tolerate the air-conditioning in the car blowing onto her feet; she was totally intolerant to cold air on her feet when the laser was applied to the right foot. A true indication of the vasomotor volatility, in the top view both feet are now responding to the ambient temperature; the actual temperature over the left PIP in the great toe is down six degrees from the initial scan nine days earlier.



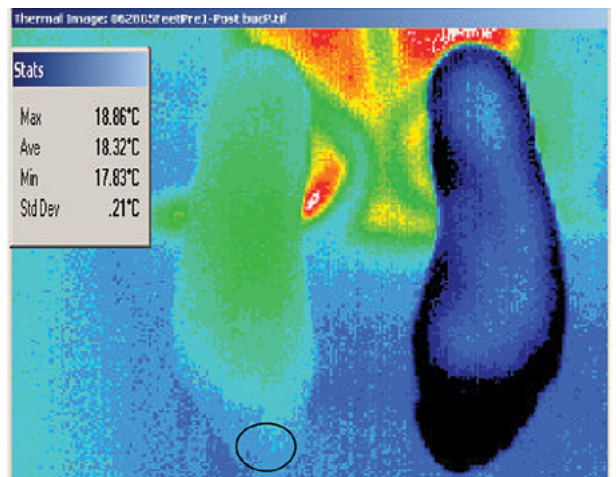
This image was made on day four of treatments to the left foot. Three consecutive Class IV laser treatments reveal the two plantar surfaces are demonstrating the best graduated thermal gradient pattern to date. The patient notes her feet do not burn during the day, they “buzz.” She continues to have some burning only in the middle of the night. At this time she is taking one Neurontin versus one every five hours. Her psychological outlook is much improved and she is already enjoying marked improvement in her activities of daily living.



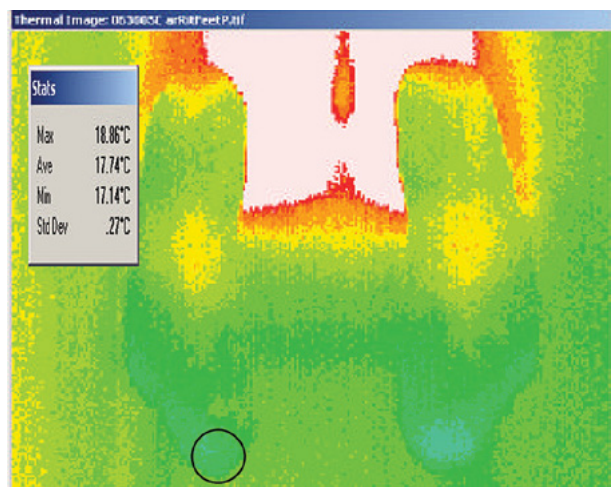
This is the pre-laser scan taken five days later. Given the marked response the patient related, the resolution to the PIP on the left great toe and a temperature differential between the two great toes was less than one half degree C, no laser therapy was applied. A “wait -and-see” approach was taken.



On the same day as the “wait-and-see” approach was taken, a cold challenge was applied to the patient’s sympathetic nervous system by having her hold a frozen soda can in each hand. The image to the left was made after four minutes.

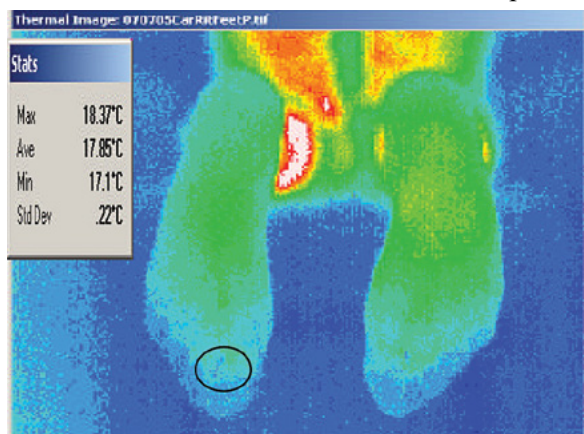


This image, made the same day, was made four minutes following another cold challenge. Here the patient placed her right foot in a bucket filled to the lower ankle with water chilled to 40 degrees C. Aside from the cold water, the patient experienced no discomfort or reaction in her left foot. As the foot warmed there was no reaction as she experienced over the previous years.

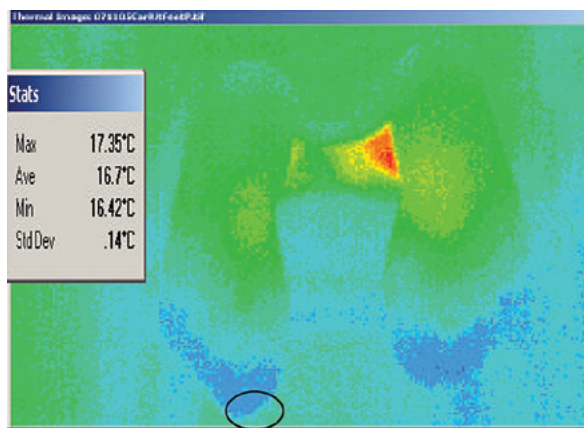


This view is two days post “cold challenge” and the great toe differential is now at .25 degrees C. She continues to enjoy a more normal appearance to her feet throughout most of the day. Even when the color changes slightly she does not experience the dramatic corresponding pain. Her feet still

burn in the middle of the night although they are fine when she wakes up in the morning. She does not demonstrate the sympathetic dominance she once did via hyperhidrosis in either the hands or the feet. Further investigation into her hormonal and glucose levels is underway. She has not received any additional laser treatment for one week at this point.



This view is two days post “cold challenge” and the great toe differential is now at .25 degrees C. She continues to enjoy a more normal appearance to her feet throughout most of the day. Even when the color changes slightly there is not the dramatic corresponding pain. Her feet still burn in the middle of the night although they are fine when she wakes up in the morning. She does not demonstrate the sympathetic dominance she once did via hyperhidrosis in either the hands or the feet. Further investigation into her hormonal and glucose levels is underway. She has not received any additional laser treatment for one week at this point.



This image is one week later, now three weeks following her last laser therapy. This person states she is now functioning better than she has since November 1998. To this point she has had only four treatments to the PIP on her left great toe with a continuous-beam Class IV therapeutic laser.

After initially treating the right foot, and observing changes in both feet, it was apparent the sympathetic sensory fibers perceived the photochemical reaction. That the patient noticed an improvement she had not seen in years, the skin began to look more normal, less cyanotic. The temperature differential was unimpressive and I did not hold out much hope the improvement would last long. The poor response to her efforts to walk on hard level surfaces confirmed my suspicion. The original plan was to apply the therapy to the right foot for the first week, so the reaction she experienced over the weekend did not trigger a change in treatment to the left foot. The hyperthermic response to the left PIP in the great toe suggested the neurovascular change there may be revealing an ephaptic peripheral nerve damage.

The dramatic response to vasomotor stability, although not perfect, indicated the PIP on the left great toe was a critical neurological lesion. In a small unmyelinated nociceptor such a reaction could be labeled an “angry back firing C fiber.” As mentioned earlier, even this diagnosis was tentative because there was no localized pain over that location nor was injury to that location reported. However, Livingston’s “vicious cycle” suggest the hyperactivity of the anterolateral horn motor cells in the spinal cord is caused by decreased input from larger proprioceptors. Livingston also noted several chemical forms of the vicious cycle, the one most suspected in this case was cholinergic stimulation which results in hyperhidrosis. This resolved with treatment. Therefore, it is concluded that although the patient is on nutritional supplementation to influence sympathetic dominance, the laser therapy was the catalyst in affecting change. The right foot did in fact serve well as a control measure. Consequently, it appears the Class IV laser therapy accelerated localized tissue recovery which in turn enabled a complete neurological circuit to bring vasomotor and sensory stability to both feet.

While concomitant physiological issues contributing to her altered physiology require ongoing investigation and treatment, Infrared Imaging has proven once again why it is the only imaging method to reveal functional changes in peripheral vascular conditions involving neuropathic pain. Any clinician addressing persons plagued by acute and chronic pain will appreciate an invaluable tool to safely, efficiently, and economically monitor peripheral vascular function as a therapeutic modality is employed. Anatomical studies such as MRI, CT, or standard x-ray lack the capacity to reveal function in the sympathetic nervous system. Likewise, no therapeutic modality aside from a continuous beam Class IV laser has the ability to penetrate surface and deep tissues. This case objectively illustrates how properly locating the involved tissue and applying the proper therapy brings about the best response, predictably and economically in term of dollars spent and production lost. Until this technology is more readily utilized in the medical market place the spiraling cost to treat chronic somatic and neuropathic pain will undermine the patients health and further tax a crippled health care delivery system. Closer to home, unexpected or ongoing medical expense is the number one reason for personal bankruptcy today. Therefore, digital infrared imaging and Class IV laser therapy have the potential to stop the pain in more ways than one!

ABOUT THE AUTHORS

Dr. Koziej is a native of Dayton, OH and has practiced at Mueller Chiropractic since 1996. He once rode his bicycle across America and has since remained physically fit. Today he helps competitive athletes and weekend warriors heal through his expertise in biomechanics. Dr. K was one of the first in Kentucky to master Class IV Laser Therapy and utilizes it to complement his expertise in spinal adjusting techniques.

Dr. Craig Mueller earned a chiropractic degree from Logan University. In addition to mastering many chiropractic adjusting techniques, he extensively studied biochemistry and the benefits of sound nutrition. Dr. Mueller received a Fellowship in Applied Spinal Biomechanical Engineering, Certification In Advanced Diagnostic Imaging and ultimately Board Certification In Infrared Imaging. He is the author of *The New Chiropractic: The Human Frame, Diet, Exercise and the Prevention of Disease*.

THE LONG TERM MANAGEMENT OF DIABETIC NEUROPATHY WITH HIGH POWER LASER THERAPY (HPLT)

Author: Joseph A. Costello Jr. DC, DABCO

CLASS IV LASER THERAPY CASE REPORT

OBJECTIVE:

To demonstrate the efficacy of High Power Laser Therapy as a treatment solution for a patient with chronic non-responsive peripheral neuropathy.

HISTORY AND CLINICAL EXAMINATION:

This patient is an 89 year old female who presented in 2007 with pain and severe burning in both feet of two years duration. She rated her pain as an eight on a visual analog pain scale at the time of presentation. She is a non insulin dependent diabetic. She had failed all types of medical management including Anodyne treatments. At the time of presentation, she was taking 1,200 mg of Neurontin per day.

CLINICAL EXAMINATION:

Peripheral pulses were diminished in the Dorsal Pedis and Posterior tibial arteries bilaterally.

NEUROLOGICAL EXAM:

DTR: 2-/2 and symmetrical. Myotomes were 5/5 and symmetrical. Sensation: revealed hypesthesia from the metatarsals to the distal phalanges bilateral. Tinel's sign was positive over the fibular heads and post Tibial nerves for radiating paresthesias.

ORTHOKINETIC EXAMINATION:

Reveled moderately advanced subtalar pronation. Dynamic gait scan revealed areas of increased pressure over the metatarsal heads.

DIAGNOSIS:

Peripheral Neuropathy resulting in Causalgia.

TREATMENT PLAN (METHODS) AND RESULTS:

The patient was fit with corrective orthotics to correct abnormal biomechanics and remove abnormal pressure areas from the plantar surface of the foot. She was then treated with High Power Laser Therapy (HPLT). The exact protocols are proprietary. After her first treatment, she indicated a significant reduction in burning pain. After completion of a course of therapeutic high power laser therapy performed three days each week for approximately 8 weeks, she was completely pain free and her sensation to pinprick had gradually increased. Her clinical exam revealed a dramatic improvement in her peripheral pulses in the ankles and feet (Dorsal Pedis and Posterior Tibial Artery). Only patchy areas of hypesthesia remained. The patient refused maintenance treatments at that time. Table 1 outlines the chronological results for the initial course of treatment.

Treatment	Wattage	Time(minutes)	Dosage(Joules)	Treatment Notes
1	2.5	30	4,500.00	Pain & burning in feet & toes
2	3.5	30	6,300.00	Noticeable improvement
3	3.5	30	6,300.00	Soreness on dorsum of foot
4	4.5	30	8,100.00	Numbness from mets to toes
5	5	30	9,000.00	Less leg/foot pain
6	5	30	9,000.00	Tightness in calf & foot
7	6	30	10,800.00	Pulses are improving with treatment
8	6	30	10,800.00	No allodynia, sensation is improved
9	6.5	30	11,700.00	Sensation to pinprick shows improvement from mets to toes
10	6.5	30	11,700.00	Stiffness on plantar & dorsum of feet
11	6.5	30	11,700.00	Mild lymphedema around lateral maleoli
12	7.5	30	13,500.00	Sensation of thickness/ stiffness on plantar surfaces of feet
13	7.5	30	13,500.00	No pain or burning, mild proprioceptive loss in feet & ankles
14	7.5	30	13,500.00	No dysesthesias in legs/feet/toes
15	7.5	30	13,500.00	Patient is asymptomatic, pulses are strong bilateral

Table 1 – Results Initial Course of Treatment

COURSE OF REGRESSION:

The patient indicated that she remained pain free for almost one year before a gradual return of her symptoms began.

TREATMENT PLAN:

The patient once again returned for HPLT. After a therapeutic course of 15 treatments, she was once again returned to a completely pain free status.

THERAPEUTIC MAINTENANCE PLAN:

She is now able to maintain her status without any activity intolerance whatsoever by participating in maintenance therapy approximately 60-90 days.

CONCLUSION:

High Power Laser Therapy has been demonstrated to accelerate nerve regeneration^{3,4} as well as vasodilation of blood vessels and neo-capillary formation^{1,2,5,6}. It is safe and virtually free of side effects. As demonstrated in this case study, HPLT is much more than a deep heating modality⁸. This opinion is proven by the fact that no other form of medical management to date has ever delivered almost twelve months of pain free living for a neuropathy patient! This would also include any form of soft tissue heating modality. Clearly at this time, a large scale blinded study with a control group and sham treatment needs to be done to further evaluate HPLT results with neuropathy patients on a long term basis.

ABOUT THE AUTHOR

Dr. Costello is a Board certified chiropractic orthopedist. He is also Board certified in quality assurance and utilization review, and has been practicing continuously in Palm Beach County for 26 years. Dr. Costello was formerly the president Florida College of Chiropractic Orthopedist (1993 to 2005), and also the chief of clinical services Avicenna Laser Technology (April 2006 through September 2011). He is a published author and lecturer on Class IV laser therapy and clinical practice.

REFERENCES:

1. Effects of infrared laser exposure in a cellular model of wound healing. Skopin M and Molitor S, Dept. of Bioengineering, University of Toledo, Toledo OH.
2. Mester E, Mester AF, Mester A (1985) The Biomedical effects of laser application. *Lasers Surg. Med.* 5:31-39.
3. Double-blind randomized study evaluating regeneration of the rat transected sciatic nerve after suturing and postoperative low-power laser treatment. *Journal of Reconstructive Microsurgery.* 2001; 17 (2): 133-137. Shamir MH, Rochkind S, Sandbank J, Alon M.
4. Effects of laser irradiation on the spinal cord for the regeneration of crushed peripheral nerve in rats. *Lasers in Surgery and Medicine* 2001, 28(3): 216-219. Rochkind S, Nissan M, Alon M et al.
5. Assessment of laser therapy for late postoperative pain after lumbar fusion surgery and for pain and wound healing after acute traumatic injury preliminary results. Biyani A, Skie M, Goel V, Ciocanel D, University of Toledo School of Medicine.
6. Class IV "High Power" laser therapy in Chiropractic and rehabilitation. Wertz R., *Dynamic Chiropractic* – 2006 vol. 24, issue 23.

THE TREATMENT OF CHRONIC REFRACTIVE RADICULOPATHY WITH HIGH POWER LASER THERAPY

Author: Joseph A. Costello Jr. DC, DABCO

CLASS IV LASER THERAPY CASE REPORT

HISTORY:

A 47 year old eastern European male patient presented with a long term history of back and left leg pain of 10 years duration. He denied any bowel and bladder signs. He had failed all forms of conservative care which was available to him in his country. He refused surgical intervention. Traditional treatment options for this patient would typically have included a series of epidural steroid injections, pain medication, acupuncture, physiotherapy, and spinal manipulative therapy.

CLINICAL PRESENTATION:

Weight: 197 lbs.

NEUROLOGICAL:

DTR: 2/2, left achilles was 1+ with reinforcement. Dermatomes reveled left S1 hypesthesia. Myotomes showed EHL's 5/5 and symmetrical. Circumferential mensuration reveled no atrophy of either calf. Heel/toe walking was also 5/5.

ORTHOPEDIC:

SLR was classic on the left for radiation into the foot @ 30 degrees, 70 degrees on the right. The left sciatic notch was exquisitely tender on the left. Springing maneuver was painful at L5/S1. Sitting SLR combined with long axis traction and popliteal compression were classic for extreme leg/buttock pain. ROM reveled that his leg pain was exacerbated by flexion and alleviated by extension.

ORTHOKINETIC WEIGHT-BEARING:

Bilateral subtalar pronation was noted more so on the right which resulted in slight inferiority of the right hemipelvis. No tibial or Femoral torsion was noted.

DIAGNOSIS:

Chronic left S1 radiculopathy complicated by kinetic chain dysfunction.

TREATMENT PLAN AND RESULTS:

Prior to initiating therapy, the patient was prescribed custom fabricate orthotics which were posted as follows: Rearfoot posting: 5 degrees varus, forefoot posting 6 degrees varus in order to correct the kinetic chain dysfunction and to create an "optimal healing environment". The patient then underwent flexion/extension provocation testing. It was noted that he had dramatic centralization of his left leg pain with hyperextension coupled with right side bending. The patient began High Power Laser Therapy (12 watts, for 10 minutes) to the following locations: L5/S1 disc, Left Sciatic notch, and left common Peroneal nerve. He was treated daily, 5 days a week, for 2 weeks. At the end of the 10 treatment sessions, the patient indicated a reduction in pain and activity intolerance of between 60-70 %. His supine and sitting root tension signs had also dramatically improved.

DISCUSSION:

Laser therapy is classified as an Actinotherapy which results in biostimulation of the Chromophores inside the mitochondria of each cell^{1,8}. This photo-stimulation results in increased cellular metabolism. Although the High Power Laser is warm, the results are photochemical and not thermal⁸. Biostimulation translates into reduction of inflammation, increased blood flow, nerve regeneration and lymphatic drainage^{5,6}. Regarding patients suffering from back and leg pain, the High Power Laser is thought to decrease inflammation of the disc and nerve root as well

Treatment	Wattage	Time (minutes)	Dosage-Joules	Treatment Notes
1	10W	25	15,000	Left leg pain appears to centralize with extension and right side bending
2	12W	25	18,000	Positive root tension signs in left leg (supine & sitting). No change after initial treatment.
3	12W	30	21,600	Slight decrease in severity of left leg pain.
4	12W	30	21,600	Pain in left buttock and left leg is intermittent at this time.
5	12W	30	21,600	Mild degree of improvement in severity of left leg pain. 5/5 power EHL, Heel/Toe walking.
6	12W	30	21,600	Continued signs of improvement regarding severity and frequency of radiation into left leg.
7	12W	30	21,600	Significant reduction in left leg pain. Mild tenderness in left sciatic notch.
8	12W	30	21,600	Dramatic reduction in left leg pain. Minimal tenderness at the lumbosacral junction.
9	12W	30	21,600	Patient reports 60% overall reduction in severity of left leg pain. No appreciable root tension signs present.
10	12W	30	21,600	Patient reports 70% overall improvement after 10 sessions. No sitting root tension signs are present. Patient had to return to Europe.

Table 1 – Treatment and Progress Note

as aid in nerve regeneration. Healing of annular defects in the outer 1/3 of the disc (which is vascularized) have the ability to heal⁹. In order to achieve optimal healing and long term results, it has been found in a clinical setting that all biomechanical abnormal forces need to be removed so healing is not interrupted or compromised during gait.

SUMMARY:

High Power Laser Therapy has the ability to reach deep within the body when compared to Low Level Laser Therapy⁸. When used in a patient who's biomechanical abnormalities have been corrected, the results achieved seem to be long term in nature. This may also be due to the fact that laser energy appears to also biostimulate collagen and fibroblast growth which would enhance the tensile strength of the annular fibers of the degenerative disc patient^{1,2,3,4}. Clearly, further investigation regarding a blinded study with pre and post MRI evaluations is necessary to help further visualize the anatomical effects of photo-stimulation with High Power Laser Therapy.

ABOUT THE AUTHOR

Dr. Costello is a Board certified chiropractic orthopedist. He is also Board certified in quality assurance and utilization review, and has been practicing continuously in Palm Beach County for 26 years. Dr. Costello was formerly the president Florida College of Chiropractic Orthopedist (1993 to 2005), and also the chief of clinical services Avicenna Laser Technology (April 2006 through September 2011). He is a published author and lecturer on Class IV laser therapy and clinical practice.

REFERENCES:

1. Effects of infrared laser exposure in a cellular model of wound healing. Skopin M and Molitor S, Dept. of Bioengineering, University of Toledo, Toledo OH.
2. Mester E, Mester AF, Mester A (1985) The Biomedical effects of laser application. *Lasers Surg. Med.* 5:31-39.
3. The influence of low level infra red laser therapy on the regeneration of cartilage tissue. P Lievens, Ph. Van der Veen.
4. Therapeutic low energy laser improves the mechanical strength of repairing medial collateral ligament. Fung DT, Ng GY, Leung MC, Tay DK, *Lasers Surg Med.* 2002; 31: 91-96.
5. Double-blind randomized study evaluating regeneration of the rat transected sciatic nerve after suturing and postoperative low-power laser treatment. *Journal of Reconstructive Microsurgery.* 2001; 17 (2): 133-137. Shamir MH, Rochkind S, Sandbank J, Alon M.
6. Effects of laser irradiation on the spinal cord for the regeneration of crushed peripheral nerve in rats. *Lasers in Surgery and Medicine* 2001, 28(3): 216-219. Rochkind S, Nissan M, Alon M et al.
7. Assessment of laser therapy for late postoperative pain after lumbar fusion surgery and for pain and wound healing after acute traumatic injury – preliminary results. Biyani A, Skie M, Goel V, Ciocanel D, University of Toledo School of Medicine.
8. Class IV “High Power” laser therapy in Chiropractic and rehabilitation. Wertz R., *Dynamic Chiropractic* 2006 vol. 24, issue 23.
9. Vascularization of the intervertebral disc in pathological conditions. Moore R, University of Adelaide, Feb. 1995

CASE STUDY LOOKING AT THE EFFECT OF CLASS IV LASER ON A PATIENT WITH RECENT POST-SURGICAL REPAIR OF A COMPLETE ROTATOR CUFF TEAR

Author: Lee E. Zohn, DC, CCSP, DAAPM

CLASS IV LASER THERAPY CASE REPORT

ABSTRACT:

OBJECTIVE:

Our aim was to report on the effects of class IV laser on a patient who had recently undergone a surgical repair of a complete rotator cuff tear. We looked at shoulder pain at rest, active shoulder range of motion, shoulder pain at end range, orthopedic testing of the shoulder and muscle strength on a 5 point grading scale.

METHODS:

One female patient (66 years of age) with recent rotator cuff surgery was seen on six separate occasions and treated with 4000 joules at CW to the right shoulder (supraspinatus tendon, teres minor, infraspinatus).

RESULTS:

Significant reduction of pain was noted on Visual Analog Pain Scale and range of motion both actively and passively was restored to normal ranges.

CONCLUSION:

The patient response demonstrated the effectiveness of class IV laser on post surgical healing and restoration of function following surgery to the right rotator cuff. All outcome measures improved dramatically. Future controlled large scale studies are needed to further investigate patient response to class IV laser.

HISTORY:

The patient is a 66 year-old retired female who complained of right shoulder pain of 3 month's duration secondary to a fall. Her pain was graded a 7/10 on the visual analog pain scale and was worse at night. Sleeping was difficult. She noted subjective loss of strength in the right shoulder, painful range of motion (ROM), loss of sleep and significant disruption in carrying out her normal activities of daily living.

Her medical history is complicated, including MS, bilateral OA at both knees, marked pes planus deformity at both feet, lumbar disc disease and disc derangement, recent tibial plateau fracture, liver disease, glaucoma, COPD, corneal transplant, Sjogren disease, and fibromyalgia.

Examination revealed active abduction of the right shoulder measuring 71 degrees at which point pain was experienced and graded 7/10. Passively, abduction was 76 degrees. Internal rotation was 12 degrees both passively and actively and sharp pain was noted. External rotation was 33 degrees actively and 39 degrees passively with pain at the anterior shoulder.

Orthopedic testing revealed a markedly positive supraspinatus press test, positive Codman's Drop Arm Test, positive Apley's inferior and superior and a negative apprehension. Impingement sign (Empty Can Test) was markedly positive.

She had tenderness at the supraspinatus tendon and biceps tendon. No swelling or edema was appreciated. Strength of the supraspinatus tendon was graded 1+/5.

MRI:

An MRI of the right shoulder was ordered and revealed a full thickness tear of the anterior aspect of the supraspinatus tendon 11 mm in AP dimension and 1.7 cm in transverse dimension. There was thickening and intermediate increased signal within the remainder of the supraspinatus tendon, as well as within the infraspinatus tendon compatible with tendonosis. There was a small amount of joint effusion. There was the question of a possible subluxation of the biceps tendon anterior to the subscapularis tendon, suggesting tearing of some of the superficial fibers of the subscapularis tendon. There was a large subacromial spur impinging upon the subacromial space.

The patient was told to follow-up with an orthopedic surgeon for further evaluation. It was recommended by the surgeon that she undergo a surgical repair of the right rotator cuff and the subacromial spur. In April of 2006, the patient underwent surgery and she relayed to me that the surgeon said it was the "worst rotator cuff tear and most difficult surgery he had ever seen."

SURGICAL NOTE:

The surgical procedure consisted of an arthroscope being through a posterior portal into the glenohumeral joint where the findings showed a full thickness tear of the supraspinatus tendon. The scope was then put into the subacromial space and a subacromial decompression was carried out including debridement of the rotator cuff tear. Through the same lateral portal, 2 opus anchors were used to do horizontal mattress sutures x2 into the supraspinatus and bring it to its bony bed insertion and attachment. This gave excellent fixation of the cuff and after copious irrigation the instruments were removed. Portals were closed with a 4-0 Monocryl subcuticular stitch. The patient went to recovery in stable condition.

Seven weeks following surgery the patient presented back to our office to see if there was anything we could do for her shoulder, as she was in a great deal of pain. Due to other health issues, she was unable to commence any type of active rehabilitation. She noted that she was improved since having the surgery, but was still in a lot of pain.

POST SURGICAL EXAMINATION:

A. ROM in Abduction = 88 degrees with pain at 8/10
A. ROM in Adduction = 23 degrees with pain at 6/10
A. ROM in Internal Rotation = 19 degrees with pain 7/10
A. ROM in External Rotation = 40 degrees with pain 4/10

P. ROM in Abduction = 100 degrees with pain at 8/10
P. ROM in Adduction = 30 degrees with pain at 6/10
P. ROM in Internal Rotation = 22 degrees with pain 7/10
P. ROM in External Rotation = 45 degrees with pain 4/10

*A. ROM-Active Range of Motion

*P. ROM-Passive Range of Motion

Gentle testing of the supraspinatus tendon (supraspinatus press test) was markedly positive with pain at 10/10. She was tender to touch over the supraspinatus tendon, AC joint and at the biceps tendon. She had moderate Trp's at the right teres minor, subscapularis and supraspinatus. Capsular restrictions were noted secondary to probable adhesions/scar tissue. positive Mild swelling was appreciated. Strength of the supraspinatus tendon was graded 2+/5.

TREATMENT:

A series of six Class IV laser treatments was recommended to the patient in an attempt to decrease pain, improve ROM and function and reduce swelling. She was seen 2x's/week for 3 weeks. It was recommended that the patient be seen 3x's/week, but due to proximity and difficulty with ambulation (other comorbidities) she was only able to come in twice a week.

At the conclusion of six treatments of Class IV Laser using 4000 joules at CW to the right shoulder and associated musculature, she was almost pain free and ROM was completely restored.

POST CLASS IV LASER ROM EXAMINATION:

A. ROM in Abduction = 180+ degrees with pain at 2/10 at end range
A. ROM in Adduction = 23 degrees with pain at 6/10
A. ROM in Internal Rotation = 19 degrees with pain 7/10
A. ROM in External Rotation = 40 degrees with pain 4/10

P. ROM in Abduction = 185 degrees with pain at 2/10 at end range
P. ROM in Adduction = 30 degrees with pain at 6/10
P. ROM in Internal Rotation = 22 degrees with pain 7/10
P. ROM in External Rotation = 45 degrees with pain 4/10

CONCLUSION:

The patient response demonstrated the effectiveness of class IV laser on post surgical healing and restoration of function following surgery to the right rotator cuff. All outcome measures improved dramatically. Future controlled large scale studies are needed to further investigate patient response to class IV laser.

ABOUT THE AUTHOR

Dr. Zohn is a Certified Chiropractic Sports Physician (CCSP) and a Diplomat of the American Academy of Pain Management (DAAPM). He is an active member of the American Chiropractic Association (ACA) and the ACA's Council on Physiological Therapeutics and Rehabilitation. Dr. Zohn is a board certified disability analyst and member of the American Back Society, and lectured on various topics including repetitive use injuries, work place injuries, acute care and whiplash related disorders. He is a graduate of Northwestern College of Chiropractic in Minnesota where he received a Doctorate of Chiropractic and a second bachelor's degree in Human Biology. His medical practice is geared toward conservative management of musculoskeletal injuries, including disc problems, neck and low back pain, headaches, pregnancy related back pain and complaints of the upper and lower extremities such as tennis elbow or rotator cuff injuries. Dr. Zohn is a former collegiate soccer player and currently a competitive table tennis player.

SHOULDER PAIN SUBACROMIAL IMPINGEMENT

Author: Jerome True, DC

CLASS IV LASER THERAPY CASE REPORT

CLINICAL HISTORY:

A 53 year old male presented with obvious signs of shoulder impingement. Symptoms gradually developed over a two-month period. The patient was unable to extend his arm forward without a jolt of pain. Abduction was cautious and slow from 0-90 degrees. He was unable to elevate or abduct beyond 90 degrees. External rotation was cautious without resistance and moderately to severely painful with any resistance. The patient was unable to move or resist his shoulder in any plane away from the body when pressure exceeded 5-10 lbs. X-rays were unremarkable for degeneration. The working diagnosis was subacromial bursitis and bicipital tendonitis.

TREATMENT PROTOCOL:

The treatment program included Class IV dual beam laser for the shoulder joint and shoulder girdle musculature for six visits and one axial decompression adjustment on the second visit to the T2-6 region of the spine. The 4D model laser was used in the treatment of this patient, using a total of 9 minutes laser therapy for the upper quarter. Technique followed a direct contact method of delivery in grid pattern. Trigger points in the shoulder girdle, rotator cuff, and posterior lower cervical intrinsic were treated on each visit. Contact was approximately 4-6 seconds per grid point in the symptomatic upper quarter areas. The estimated dose was 4-6 Joules of laser delivered at the skin surface per point.

RESULTS OF TREATMENT:

The patient experienced dramatic reduction of pain on the first visit and was almost symptom free in three visits. On his sixth visit, the patient reported he only had very little pain but he had returned to full capacity manual labor. He has returned to normal activities without any signs of impingement. His only residual symptom at three months post treatment was a very mild tenderness in the lateral subacromial region on deep palpation. He has remained symptom free at this point for over a year.

DISCUSSION:

The healing mechanism of laser therapy is termed photobiostimulation. There are four categories of biological effects demonstrated to occur. The first is Thermal; class IV laser has a warming effect on tissues improving flexibility of joints. The second is Biochemical; this is seen on a cellular basis with increased nitric oxide production and increases in enzyme activity. The third effect is Bioelectric; this occurs with membrane electrical gradient shifts and generation reactive oxygen species. The fourth effect is Bioenergetic; with influence on acupuncture meridians and system-wide clinical effects such as increased or decreased fatigue. There are many studies in animals and cell cultures, which demonstrate physiological effects such as increasing ATP production, increasing vasodilatation, relaxing spasm, and reduction of pain. The mechanism of pain relief and return of shoulder function in this patient appears to be the result of thermal and biochemical effects.

Lasers are classified by their output strength and wavelength of light. Class I lasers are not regulated because their output is not strong enough to cause any tissue damage. Class II lasers operate at 1mw or less. These are commonly used in laser pointers and electronic equipment such as CD players. Class III lasers have an output below 500mw they are used in many low level lasers. Class IV lasers have an output above 500mw. An example is an infrared dual-beam Class IV laser. This device has an output power ranging from 100mw-6000mw.

ABOUT THE AUTHOR

Jerry True, D.C., FIACN is a chiropractic neurologist in private practice and has over 25 years of practice experience in functional neurology, clinical nutrition, and wellness care. He has lectured throughout United States on the topics of laser therapy and neurology for multiple continuing education venues. Dr. True is the co-author of the textbook on neurology titled *Myelopathy, Radiculopathy and Peripheral Entrapment Syndromes*, and has contributed book chapters and illustrations to textbooks on sports medicine, neurology and soft tissue medicine. He has also contributed to research and published articles on laser therapy.

RESOLVING TMJ WITH CLASS IV LASER THERAPY

Author: Joseph A. Costello Jr. DC, DA BCO

CLASS IV LASER THERAPY CASE REPORT

This is a case study of a thirty two year old woman with a history of intractable TMJ and facial pain for nine years. She had seen dentists, oral surgeons, pain management specialists, a neurologist, a chiropractor, physical therapists and an ENT. She has seen a DMD who specialized in TMD. None of the therapies were successful. She saw her current primary care provider, an internist, for the first time on October 12, 2005. Her doctor called and asked if she might be a candidate for laser therapy. She was referred to Jerry Koziej, DC (the author) the same day for consultation and examination as a possible candidate for Class IV infrared laser therapy.

Prior to that she had considered Botox therapy as the next step. Her medical history which complicates treatment for her TMD is a history of ulcerative colitis requiring a total colectomy. She was unable to tolerate multiple oral medications. At the time of initial evaluation by me she had been giving samples of Celebrex and Skelaxin that day which are anti-inflammatory and muscle relaxant, respectively. She had not taken either medication at the time of my initial evaluation. She had also seen a chiropractor and found that cervical manipulation gave her relief for 24-48 hours.

She presented with TMJ pain, facial pain, bilaterally, exacerbated by any jaw movement, including smiling, talking, chewing, and brushing her teeth. Her symptoms were progressively getting worse, extending to her neck, trapezius. She said her jaw “zigzagged” as she opened and closed it. She had tried mouth bite guards muscle stimulation, physical therapy, medications, lidocaine and steroid injections into her TMJ. She was considering botox injections by an ENT in Lexington.

This is the medical history as related by the patient for TMD:

PURCHASES

2005	Purchased a Sleep Number Bed and a memory foam pillow.
2000	Purchased a TENS unit.
1999-present	Purchased magnets

PHYSICIANS

2005-present	New primary care doctor referred for laser therapy
2000-present	Chiropractor – cervical manipulation.
2005	Visit to TMD specialist DMD
1998-present	DMD – night guard prescribed
2000	Neurologist diagnosed her with Shy-Drager syndrome
1999	MRI

ALLERGY AND SINUS

2004	ENT for reconstructive sinus surgery.
Multiple times	Asthma inhalers, allergy medications, allergy shots and drops.

PHYSICAL THERAPY

1998	Ultrasound over her TMJ and surrounding tissues.
2000	Stretching exercises

OTHER

2004	Therapeutic massage
2005	Yoga and resistance exercise
2003	One session of acupuncture
Entire colon removed in 1996 due to serious ulcerative colitis. Two months later ileostomy reversal.	

MEDICATIONS

800 mg Ibuprofen	It worked immediately, but upset stomach too much.
Naproxen	stomach upset.
Skelaxin	No comment by patient.
Vicoden	Intolerable side effects.
Hydrocortizone	Intolerable side effects.
Effexor	Intolerable side effects, less severe than others.
Xanax	Intolerable side effects.
Amytriptiline	Intolerable side effects.

Upon inspection, the patient appeared distraught, tense, and in obvious pain. She was relatively expressionless. She had somewhat of pallor. She found it difficult to talk, and this author found it difficult to understand her at times. Cervical spine and cranial nerve examination were unremarkable.

The TMJ region and muscles of mastication were tender to palpation.

MATERIALS AND METHODS

Infrared images were taken to see if information of diagnostic value could be gleaned, and to establish a base line to determine if pre- and post-treatment images would reveal changes. Thermal images were obtained by a Meditherm high-resolution digital infrared thermal imaging scanner. The patient was disrobed from the waist up, acclimated to the imaging room at 69 degrees ambient temperature and positioned to view the anatomy being scanned. The A-P head and face image was taken, and left and right lateral head and face images.

The patient was to return in two days to begin treatment. The laser used was an Avicenna class IV infrared laser. Two wave lengths of light are generated: a visible red light at 635 nm, and infrared wavelength at 980 nm. A “template” was made using a small piece of cardboard

with a 2 cm x 3 cm hole cut out of it to ensure that the same area in square centimeters was lasered each treatment. This was affixed to the patient's face. The template was placed so that on the right side, the TMJ occupied the left superior-posterior corner of the hole, (the "northwest" corner) and on the left, the right posterior-superior corner (the "northeast" corner). The hand-held wand stylus was secured to the wand so the laser was at a constant 2 cm distance from the patient. The stylus was kept in constant light contact to ensure that the laser wand stayed at a consistent distance.

TREATMENT

The first four treatments were focused solely on the TMJ. The following treatments focused on both the TMJ and maxillary sinuses, using the same template to ensure consistency.

Joules = watts x seconds

Power density = watts / area in centimeters (w/cm sq)

Time in minutes

Distance in centimeters

Date	Watts	Joules	Location	Time	Power Density	Distance
10/14	4.0	1200	Rt TMJ	5	.7	2
10/19	5.0	1200	Rt TMJ	4	.8	2
	5	1200	Lt TMJ	4		2
10/20	5	1800	Rt TMJ	6		2
	5	1800	Lt TMJ	6		2
10/24	5	1800	Rt TMJ	6		2
	5	1800	Lt TMJ	6		2
10/27	5	1800	Rt TMJ	6		2
	5	1800	Lt TMJ	6		2
	5	1200	Rt max sinus	4		2
	5	1200	Lt max sinus	4		2
11/02	5	1800	Rt TMJ	6		2
	5	1800	Lt TMJ	6		2
	5	1200	Rt max sinus	6		2
	5	1200	Lt max sinus	6		2
11/16	5	1800	Rt TMJ	6		2
	5	1800	Lt TMJ	6		2
	5	1200	Rt max sinus	4		2
	5	1200	Lt max sinus	4		2
11/30	5	1800	Rt TMJ	6		2
	5	1800	Lt TMJ	6		2
	5	1200	Rt max sinus	4		2
	5	1200	Lt max sinus	4		2
12/21	5	1500	Lt pterygoid & masseter	6	.31	(.3)
	5	1500	same	6	.31	

A visual analogue scale was used for the last three treatments. I assigned "10" to be the pain she had when she first came to the office,

and "0" to be no pain. the patient circled a number on the form itself. The values are as follows:

Date	pre-treatment	post-treatment	Time
11/02	0	0	4 days after previous treatment
11/16	2.5	0	2 weeks
11/30	1.5	0	2 weeks
12/21	1.5	0	3 weeks

(The patient had had a sinus infection the previous week, [12/14] and thought her pain was because of sinus fullness)

The patient was to return on December 14, but cancelled due to illness.

Another series of thermal images were taken on 11/30/05. the Meditherm program allows us to fix the cursor on any point of the image and gives us the absolute temperature in degrees Celsius. The cursor was used to draw a small square over the areas of the face, bilaterally and symmetrically, and the program was able to give an average temperature of the enclosed area. The sinuses and temporomandibular joints were compared left to right, and pre- and post-laser treatment.

The temperature of her face was recorded in degrees Celsius:

PRE-TREATMENT:

A-P	right maxillary sinus: 24.36	left maxillary sinus: 24.50
Left lateral TMJ:	27.15	
Right lateral TMJ:	27.09	

POST-TREATMENT:

A-P	right maxillary sinus: 22.99	left maxillary sinus: 22.98
Left lateral TMJ:	25.09	
Right lateral TMJ:	25.46	

DELTA T (difference between pre- and post-treatment temperatures)

Right maxillary sinus:	1.37
Left maxillary sinus:	1.52
Right TMJ:	1.63
Left TMJ:	2.06

PATIENT COMMENTS

- 10/14 (After treatment) her right jaw was "not grinding".
- 10/19 "Big improvement".
- 10/20 She was "sleeping better" and in the morning "felt refreshed".
- 10/24 She had some pain but was "relaxed".
- 10/27 There was no jaw "deviation" when she opened her mouth. (She described a lateral "zigzag" motion of her jaw as it opened and closed)
- 11/16 She was completely pain-free until a few days before, then a little tightness in her cheeks. There was no "clicking" in her jaw.
- 11/30 There was "hardly any pain".

DISCUSSION

There has been a growing interest in the last two decades in TMD as a cause of facial and head pain. Mechanical disorders of the joint, congenital and acquired deformities can all give rise to head and facial pain.

The temporomandibular joint (TMJ) is a gliding joint, formed by the mandible and temporal bone. The articular surfaces of the of the mandible and temporal bone are separated by and articular disk, which divides the joint cavity into two small spaces.

TMJ syndrome or temporomandibular disorder (TMD) is the

most common cause of facial pain after toothache. There is no clear agreement as to an exact definition. Broadly, TMD is (1) secondary to myofascial pain and dysfunction (MPD) or (2) secondary to true articular disease. The majority of cases are myofascial in origin. It is frequently associated with bruxism and daytime jaw clenching. The muscular pain will mimic TMD, when actually it is dysfunction of the muscle rather than derangement of the joint itself.

TMD affects more women than men, at a ratio of 4:1. Incidence is higher in young adults.

Pain can be exacerbated by chewing. It can be unilateral or bilateral. There may be clicking or popping of the joint. The muscles can feel stiff. There may be limited jaw opening. Pain can be present over the TMJ, cheeks, neck and into the shoulder. One third of the patients have a history of psychiatric problems. On palpation, there may be joint and muscular tenderness.

The masseter muscle refers pain to a number of areas, with some broader spillover areas. Different parts of the muscle refer to different areas of the face. This includes the cheek, lower jaw, superciliary arch, and the zygomatic arch near the ear. Pain can also be referred to the ear.

Pain can be referred to the lower occiput. The masseter is innervated by the masseteric nerve that arises from the anterior branch of the mandibular division of the trigeminal nerve. The referral patterns will often mimic TMJ pain.

The medial pterygoid is innervated by the medial pterygoids nerve which is from the mandibular division of the trigeminal nerve. This will refer pain to the TMJ, and lesser so to the angle of the mandible. Pain is increased by attempts to open the mouth wide for eating. The lateral pterygoids will refer pain to the TMJ and the area over the maxillary sinuses. There can be autonomic concomitants of excessive secretion from the maxillary sinus, mimicking sinusitis. Dysfunction of the lateral pterygoids can produce clicking sounds.

The patient was experiencing increasing pain in her neck spreading across the trapezius to the shoulders. The sternocleidomastoid can refer pain to the cheek, forehead and ear. The trapezius refers to the side of the neck, zygomatic arch, and angle of the mandible.

The maxillary division of the trigeminal nerve supplies sensation to the upper jaw cheeks, maxillary sinuses and part of the external ear. The mandibular branch for the Vth supplies the lower jaw, and buccal mucosa. Motor fibers supply the muscles of mastication: masseter, temporal, internal and external pterygoids. The facial nerve supplies motor nerves to the superficial facial muscles. There are also some proprioceptive fibers carrying deep pressure and position sense from the facial muscles.

Once the laser beam contacts the skin, some of the photons scatter. While lasing the TMJ, some of the photons would have scattered anteriorly and medially, into the muscles of mastication, and also contacting sensory nerve endings in those areas. It was curious at first that she got the most relief after lasering her maxillary sinuses. After some reflection, it seemed that her TMD might be secondary to myofascial dysfunction of the muscles of the face and

mastication. The muscles were inadvertently lased while lasing the maxillary sinuses. The pain actually may not have been even caused by TMD; the facial pain and myofascial dysfunction may have caused any facial pain and TMD present.

The return of normal function of the muscles would have normalized function of the TMJ. The patient reported that her bite had been altered.

There are differences between TM pain, and TM dysfunction. The pain is directly related to jaw movements, mastication and to palpation. Dysfunction shows restricted movement of the mandible, clicking and changes in occlusion. Did this patient show TMD to be secondary to myofascial dysfunction? The causal relationship should be established. Myofascial pain in the face is also produced by malocclusion. Does muscular dysfunction cause the joint dysfunction or is the reverse true?

There are two reflexes that control muscle function: the muscle spindles and Golgi tendon organs. Muscle spindles lie between regular muscle fibers, and are termed extrafusal fibers. The muscle spindle is composed of a number of specialized muscle fibers called intrafusal fibers. Sensory nerves are wrapped around the spindle and transmit information to the CNS as to the state of stretch. In the spinal cord, these nerves synapse with an alpha motor neuron which triggers reflexive muscle contraction to resist further stretch. Gamma motor neurons excite the intrafusal fibers causing a slight pre-stretch. This makes the muscle spindle very sensitive to small degrees of stretch. This information is also sent to the brain, for exact length and contractile state, as well as the rate of change of stretch. This is to maintain muscle tone and posture, and for executing movements.

The Golgi tendon organs are small encapsulated sensory receptors located just proximal to the tendon fibers' attachment to the muscle. Whereas the muscle spindle senses length, the GTO senses tension, the amount of force exerted on the tendon. They are very sensitive and can detect strain on a single muscle fiber. These are inhibitory in nature; their function is in protection of the muscle. When stimulated, they inhibit the agonist muscle and stimulate the antagonist muscle.

Does muscle spasm need to be present to restrict the joint, or a dysfunction of the muscle spindles and Golgi tendon organs? What are the physiological effects of the infrared beam on these structures? How are changes in cell wall permeability affecting these structures?

MPD can be frustrating both for the patient and physician. It may be that primary care physicians are frustrated because of an incomplete knowledge of neuromuscular function. There is not a way to look at MPD through any imaging techniques, X-ray, MRI, CT, etc, nor is there a lab test, with the possible exception of CPK. Without these there needs to be an understanding of neuromuscular functional anatomy, along with the right questions asked during the history. Applying Occam's razor, one should first think myofascial dysfunction, and direct treatment towards that. Muscles play an extremely important role in the pathogenesis and management of various pain

syndromes. Even if muscle pain is considered, and analgesics or anti-inflammatory drugs are given, muscle function needs to be addressed. Jumping to Shy-Drager syndrome as her neurologist did is akin to hearing hoofbeats and thinking Mongolian Yak. It is possible, but very unlikely.

In future cases of this type, another objective measuring device should be used. While infrared imaging is very sensitive, it is not specific. Many variables come into play in thermographic imaging – ambient temperature, make-up, skin lotions, and blemishes – and have to be taken into consideration. However, infrared thermography is sensitive to increases in temperature due to inflammation. One must be careful to take into account the other factors that may give “false positives.” The changes in pre- and post-treatment skin temperatures may well have been to a decrease in inflammation in the target tissues, or a decrease in metabolic activity of the muscles as they maintained a hyper tonic state. EMG might be useful to determine activity of the muscles pre- and post-treatment. Other devices should be considered as well, such as inclinometers, electrogoniometers, or simple linear measurements such as measuring the distance between the patient’s upper and lower incisors, pre- and post-treatment.

The infrared laser creates a number of physiological and biochemical changes in the tissues. The beam stimulates blood vessel endothelial cells to secrete a vasodilator termed endothelium-derived relaxing factor, which is nitric oxide (NO, specifically produced by NOS-3), causing the underlying smooth muscles cells to relax, dilating the blood vessels, increasing the amount of nutrients and oxygen to the target area. This also allows greater drainage of lymphatic fluid decreasing swelling of the target tissue and surrounding tissues. NO also inhibits the aggregation of platelets and keeps inappropriate clotting from interfering with blood flow. The NO produced by NOS -3 also inhibits inflammation of the blood vessels by blocking exocytosis of mediators of inflammation from the endothelial cells. Among these are histamines and bradykinins, which themselves are irritants to surrounding nerve endings.

The laser has antimicrobial properties, which is related to the specific infrared wavelength itself, but also to the fact that NO aids in the killing of engulfed pathogens by macrophages. This is a “double punch” in that NO brings more blood to the area by vessel dilation, bringing more leukocytes, and aiding in pathogen destruction.

The infrared beam accelerates wound healing by stimulating fibroblast production of collagen, and increased organization of tissue granulation.

Other effects which expedite wound healing include change in cell wall permeability, mitochondrial wall permeability, and increased production of serotonin.

CONCLUSION

This case shows evidence that class IV infrared laser therapy may be an effective, non-invasive modality for some types of intractable pain. It also gives us evidence that infrared imaging may be useful in demonstrating effectiveness of a particular modality. It also seems reasonable, based on the literature and this case history, to first consider myofascial dysfunction as a cause of TMD. I believe this case shows that more research is warranted to fully explore the possibilities of using the class IV infrared therapeutic laser in TMD.

ABOUT THE AUTHOR

Dr. Costello is a Board certified chiropractic orthopedist. He is also Board certified in quality assurance and utilization review, and has been practicing continuously in Palm Beach County for 26 years. Dr. Costello was formerly the president Florida College of Chiropractic Orthopedist (1993 to 2005), and also the chief of clinical services Avicenna Laser Technology (April 2006 through September 2011). He is a published author and lecturer on Class IV laser therapy and clinical practice.

REFERENCES:

1. Chusid, Joseph G. *Correlative Neuroanatomy and Functional Neurology*. Lange Medical Publications, 1985.
2. Chaudhary, Arun. *Temporomandibular Joint Syndrome*. June 30, 2004. (article) emedicine.com/neuro/topic366.htm.
3. Travell, Janet; Simons, David. *Myofascial Pain and Dysfunction*. Williams and Wilkins, 1983.
4. Feneis, Heinz. *Pocket Atlas of Human Anatomy*. Georg Thieme Publishers, 1976
5. Dvorak, Jiri; Dvorak Vaclav. *Manual Medicine*. Thieme Medical Publishers, 1990.
6. Bradley, Walter, et.al. *Neurology in Clinical Practice*. Butterworth Heinmann, 2000.
7. Domholdt, Elizabeth. *Physical Therapy Research, Principles and Applications*. W.B. Saunders Company, 2000.
8. Janda, Vladimir. *Muscles and Cervicogenic Pain Syndromes. Physical Therapy of the Cervical and Thoracic Spine*, 1988. Reprinted by permission of the W. B. Saunders Company.
9. Clark, James. *Clinical Dentistry*. J.B. Lippincott Company, 1990
10. Isselbacher, K, et.al. *Harrison’s Principles of Internal Medicine*. McGraw-Hill, 1994.
11. Wilmore, Jack; Costill, David. *Physiology of Sport and Exercise*. Human Kinetics, 1994.
12. Hamill, Joseph; Knutzen, Kathleen. *Biomechanical Basis of Human Movement*. Williams & Wilkins, 1995.

A RANDOMIZED CONTROLLED TRIAL FOR THE EFFICACY OF THERAPEUTIC CLASS IV LASER TREATMENT FOR TENDINOSIS

Authors: Delia Roberts, FACSM¹, Roger Kruse, FACSM², Matthew Petznick², Jacklyn Kiefer², Peter Alaskym², Stephen Stoll².

¹Selkirk College, Castlegar, BC, Canada.

²ProMedica, Toledo, OH.

CLASS IV LASER THERAPY CASE REPORT

ABSTRACT:

There is little consensus regarding effective treatments for tendinosis. Low level laser therapy (LLLT) has been shown to be effective at the cellular level, increasing cytochrome C oxidase production and reversing the effects of cellular inhibitors of respiration. Previous studies on LLLT have used class III lasers (output less than 0.5W); however, recently a dual wavelength (980/808 nm) class IV laser has been developed for use in LLLT (power output 10W). These instruments can deliver 8-9 J/cm², achieving a photochemical biomodulatory dose in only minutes. The potential for a fast, safe and effective treatment warrants further investigation.

PURPOSE:

To determine the efficacy of a class IV laser for the treatment of chronic epicondylitis.

METHODS:

Ten subjects volunteered to participate in a double blinded randomized study using LLLT (LiteCure LCT 1000), or an identical sham in which the laser was replaced with a red incandescent light. Subjects underwent clinical examination (measures of pain, range of motion, strength and ultrasonic imaging) to confirm the diagnosis of chronic tendinosis of the extensor carpi radialis brevis tendon followed by eight treatments of 10 J/cm² over 18 days. The clinical exam was/will be repeated at completion of the treatments and at 3, 6 and 12 months post-treatment.

RESULTS:

No differences were noted between the two groups for any parameter before treatment. The mean duration of symptoms was 14.5±12 months, all subjects displayed pain and loss of strength and range of motion on the afflicted side, as well as ultrasonic evidence consistent with chronic tendinosis. There was a trend for increased strength (control change = -0.4±5.3 kg; LLLT change +0.8±3.7 kg; p<0.07) and decreased pain rating (change control = +0.6±3.3 units, 1/5 decreased pain; change LLLT= -2.6±3.3 units, 4/5 decreased pain; p<0.06) in the treatment group compared to the placebo group at the first post treatment exam.

CONCLUSION:

Preliminary results suggest that LLLT is efficacious for the treatment of chronic epicondylitis. However, it remains to be seen whether statistical significance will be achieved with a larger group and whether the ultrasonographic evidence will indicate improved tendon health at 3 months.

ABOUT THE AUTHORS

Dr. Delia Roberts is an Instructor for the Biology & Kinesiology Programs at Selkirk College and President & Chief Research Scientist, FitSafe Solutions Inc. She earned a BSc (Distinction) MSc in Exercise Biochemistry, and a PhD – Medical Science (U of Calgary). She is also a Fellow of the American College of Sports Medicine, Biology, NISOD 2007. Email: droberts@selkirk.ca

Roger Kruse, MD is a board certified Family Medicine and Sports Medicine and a member of ProMedica Physicians in Regenerative Medicine. Nationally and Internationally known for leadership in Sports Medicine and Musculoskeletal Medicine, Dr. Kruse utilizes his philosophy of “treat the whole patient individually”. This philosophy of diet, exercise, preventive medicine, and now Regenerative Medicine has been used on patients and athletes throughout the country.

ProMedica Regenerative Medicine
2865 N. Reynolds Rd., Suite 142
Toledo OH, 43615
Phone: 419-578-7515
Email: ProMedicaRegenerativeMedicine@ProMedica.org

EFFECTS OF 980 NM WAVELENGTH INFRARED LASER EXPOSURE IN A CELLULAR MODEL OF WOUND HEALING

Authors: Mark D. Skopin, PhD and Scott C. Molitor, PhD

Department of Bioengineering, University of Toledo, Toledo OH

CLASS IV LASER THERAPY CASE REPORT

ABSTRACT

BACKGROUND:

Clinical studies have demonstrated beneficial outcomes for low-level laser therapy (LLLT) using near-infrared (NIR) wavelengths. It has been hypothesized that the benefits of NIR LLLT are due in part to the thermal effects of NIR exposure. However, it is not clear whether photochemical interactions between NIR light and superficial tissues contribute to beneficial outcomes. To investigate the photochemical effects of NIR exposure, the efficacy of 980 nm NIR LLLT on human fibroblast growth rates is investigated using an in vitro model of wound healing. METHODS: A small pipette is used to induce a wound in fibroblast cell cultures, which are imaged at specific time intervals over 48 h and exposed to a range of laser doses (1.5-66 J/cm²) selected to encompass the range of doses used during other in vivo and in vitro studies. For each image acquired, wound sizes were quantified using a novel application of existing image processing algorithms.

RESULTS:

Cell growth rates were compared across different laser exposure intensities with the same exposure duration, and across different laser exposure durations with the same exposure intensity. Exposure to low- and medium-intensity laser light accelerates cell growth, whereas high-intensity light negated the beneficial effects of laser exposure. Cell growth was accelerated over a wide range of exposure durations using medium-intensity laser light, with no significant inhibition of cell growth at the longest exposure durations used in this study. CONCLUSION: Low-level exposure to 980 nm laser light can accelerate wound healing in vitro without measurable temperature increases. However, these results also demonstrate the need for appropriate supervision of laser therapy sessions to prevent overexposure to NIR laser light that may inhibit cell growth rates observed in response to lower intensity laser exposure.

To investigate the efficacy of low-level exposure to 980 nm laser light, we have measured cell growth rates following wound induction using an in vitro model of wound healing. A small pipette was used to mechanically induce a wound in fibroblast cell cultures, which were then imaged at specific time intervals following wound induction and exposure to various doses of laser light. Our results show that exposure to low and medium intensity laser light significantly accelerate cell growth; high intensity laser light negated the beneficial effects of laser exposure on cell growth. Further experiments demonstrated that cell growth was accelerated over a wide range of exposure

durations using medium intensity laser light with no marked reduction in cell growth at the longest exposure durations. Our results confirm clinical observations that low-level exposure to 980 nm laser light can accelerate healing of superficial wounds. However, these results also demonstrate the need for appropriate supervision of laser therapy sessions to prevent overexposure to laser light that may reverse increases in cell growth rates observed in response to lower levels of laser exposure.

INTRODUCTION

Photobiotherapy is the clinical application of light for healing decubitus ulcers (bedsores) and other superficial wounds. Previous studies have demonstrated significant clinical value for the use of low-level laser light to accelerate the healing of superficial wounds (Mester et al., 1985). Although the cellular mechanisms of this accelerated wound healing are not known, a recent study has demonstrated that low-level light from a 633 nm HeNe laser accelerates cell growth in a cellular model of wound healing and improves cellular metabolism in a dose-dependent manner (Hawkins and Abrahamse, 2006).

The use of infrared (IR) light may have significant advantages compared to visible light for clinical applications. In particular, the longer wavelength light minimizes scatter produced by superficial layers of the skin, and allows for a penetration of the light into deeper layers of skin that are most active during wound healing processes. In addition, IR light produces heating of deeper skin layers, promoting increased blood flow and to further accelerate healing processes (Dierickx, 2006).

Although IR light has demonstrated clinical value, the effects of IR light at the cellular level have not been examined. To determine whether IR can improve cell growth and recovery, we have utilized a clinical IR laser in a cellular model of wound healing. Our results show that limited doses of IR light can increase the rate of cell growth within hours of light exposure.

METHODS

CELL CULTURE

Fetal human skin fibroblast cells (cell line CCD-1070SK, American Type Culture Collection) were grown in Dulbecco's modification of Eagle's medium (DMEM) supplemented with 1 mM L-glutamine, 1% penicillin-streptomycin and 3% fetal bovine serum. The cultures were incubated at 37 °C with 95% O₂ – 5% CO₂ at 85% humidity. Cells were trypsinized using a 0.25% (w/v) trypsin and 0.03% EDTA solution in DMEM and seeded into sterile 35 mm polystyrene culture dishes at a density of 7.0 x 10⁴ cells per cm². Cells were incubated overnight

to allow the cells to recover from trypsinization and to adhere to the bottom of the culture dishes.

WOUND HEALING MODEL

Culture dishes with plated cells were removed from the incubator, placed on the stage of an inverted microscope equipped with relief contrast optics (IX-71, Olympus) and visualized using a 4x, 0.13 numerical aperture objective. To simulate a wound, confluent monolayers were scratched with a sterile pipette approximately 1 mm in diameter (figure 1). Following wound induction, the output of a 7.5W, 980 nm laser used for clinical applications (VTR 75, Avicenna Laser Technologies) was focused on a spot 12.5 mm in diameter centered on the wound with the visible red aiming beam disabled. Cell growth into the wound region at time intervals up to 48 hours post-exposure was compared to control dishes in which no laser light was used. To attenuate the laser output and focus the light on a smaller spot, a 3 mm fiber approximately 1.5 m in length was coupled to the laser output and directed toward the center of the 35 mm culture dish approximately 10 mm above the dish surface. Two different sets of experiments were performed: the first compared different exposure intensities over the same exposure time, the second compared different exposure times at the same exposure intensity. For the first set of experiments, the laser output was varied from 1.5-7.5 W to produce exposure densities 26-120 mW/cm² for 2 minutes, resulting in exposure doses from 3.-14.4 J/cm². For the second set of experiments, the laser output was fixed at 4.5 W or 73 mW/cm² and the exposure times were varied from 20 sec to 15 min, resulting in exposure doses from 1.5-66 J/cm².

IMAGE ACQUISITION AND ANALYSIS

To assess the growth of cells back into the wound region, images were acquired at hourly intervals up to 8 hours after wound induction and laser exposure, and then at 24 and 48 hours post exposure. To maintain a controlled environment, culture dishes were returned to the incubator between image acquisition sessions.

Images were acquired using a Quantix 57 scientific grade digital CCD camera (Roper Scientific) using custom made software designed to run under Matlab (Mathworks). To assess cell growth, an automated analysis routine was developed to measure the area of the imaged field that was covered by cells. This procedure utilized the Matlab edge detection function `edge()` with the Canny algorithm option to detect lines of pixels along cell edges. Once edges were detected, the Matlab function `imclose()` was utilized to fill in the gaps between edge lines using circular structuring elements approximately one cell width across (12-15 pixels). The result of this analysis was the detection of pixels in regions covered by cells where edges were in proximity, whereas regions such as the wound that had little or no cell coverage were left undetected. Cell coverage area was then quantified at each time interval following wound induction and laser exposure by adding the number of detected pixels and comparing this to the coverage area immediately following wound induction. For each laser exposure dose and time interval following

wound induction, images were acquired from five different culture dishes to provide repeated data samples for statistical analysis.

STATISTICAL ANALYSIS

To separate the effects of recovery time and laser exposure dose, a two-factor analysis of variance (ANOVA) was performed on the cell coverage area data obtained from images acquired at different post-exposure elapsed times and from different laser exposure doses. Without any laser exposure, a complete re-growth of fibroblast cells into the wound region will occur over the 48 hour period during which cells were imaged. Therefore, a statistically significant increase in cell coverage area will occur over the course of the experiment. However, the two-factor ANOVA procedure allows for the separation of two experiment factors, in this case elapsed time and laser exposure dose. Therefore, statistically significant effects of laser exposure dose can be compared to the effects of elapsed time, and can provide an estimate of the acceleration of cell growth by the various laser exposures. The statistical software package Minitab 14 (Minitab Inc.) was utilized to perform the two-factor ANOVA; data was entered as three columns with elapsed time, exposure dose and percent increase in cell coverage area from images immediately taken after wound induction.

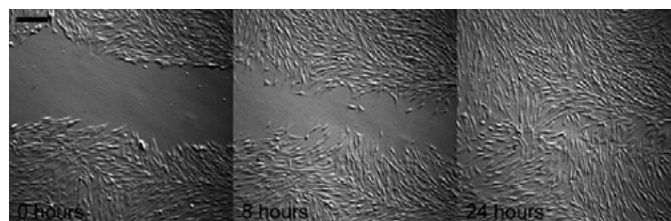


Figure 1: cell culture model of wound healing. A sterile pipette approximately 1 mm in diameter is used to induce a wound in a monolayer of fibroblast cells plated onto 35 mm culture dishes (far left image). Fibroblast cells grow back into the wound region within 8 hours (middle image) and the wound is completely overgrown within 24 hours. Scale bar: 250 μ m. The algorithm used to calculate cell coverage area found that 64.9%, 76.7% and 97.7% of the imaged area was covered with cells in the three images displayed above.

RESULTS

Our results demonstrate that exposure to light from a 980 nm laser can enhance cell growth rates in an in vitro wound model. A range of exposure doses was investigated by varying laser output power over a fixed exposure duration, or by varying exposure duration at a fixed laser output power. Figure 2 shows the results of the first experiment in which laser output power was varied from 1.5-7.5 W to produce an exposure level of 26-120 mW/cm² over a two minute exposure, resulting in exposure doses from 3.1-14.4 J/cm². Regardless of exposure level, significant cell recovery was observed within three hours of wound induction; however, exposure to moderate levels of laser light (26-97 mW/cm²) appeared to enhance cell growth at all time intervals relative to control experiments in which no laser exposure was applied (figure 2, top panel). These results were confirmed by the results of a two-factor ANOVA (figure 2, lower right), which shows that significant increases in cell growth were observed with

two minute exposures to 26-73 mW/cm² ($p < 0.01$) and 97 mW/cm² ($p < 0.05$). These results also show that the beneficial effects of laser exposure are negated by over-exposure: fibroblasts exposed to 120 mW/cm² of laser light for two minutes did not show any significant increase in growth rates relative to control experiments.

The two-factor ANOVA analysis also provided a measure of how much cell growth was accelerated by laser exposure. Over the first eight hours following wound induction, the average cell coverage increased linearly by approximately 1.7% per hour (figure 2, lower left); the growth rate begins to slow before 24 hours, when cells across the wound margin begin to contact each other and completely fill the area previously devoid of cells. When compared to the mean cell growth measured at various time intervals following wound induction, the 4-6% increase in cell growth produced by 49-73 mW/cm² of laser exposure over a two minute period represented an acceleration of wound healing by approximately 2.5-3.5 hours within the first eight hours of healing. This represents a sizeable acceleration in cell growth considering that the wounds from our in vitro model were nearly completed healed within 24 hours following wound induction. Despite the significant increases in cell growth across various time intervals and exposure levels, the two-factor ANOVA analysis did not find any significant interaction between elapsed time and exposure level. In other words, the various exposure levels showed consistent effects across all time intervals following wound induction, and there were no exposure levels whose effects were only observed at a particular time interval or subset of time intervals following wound induction.

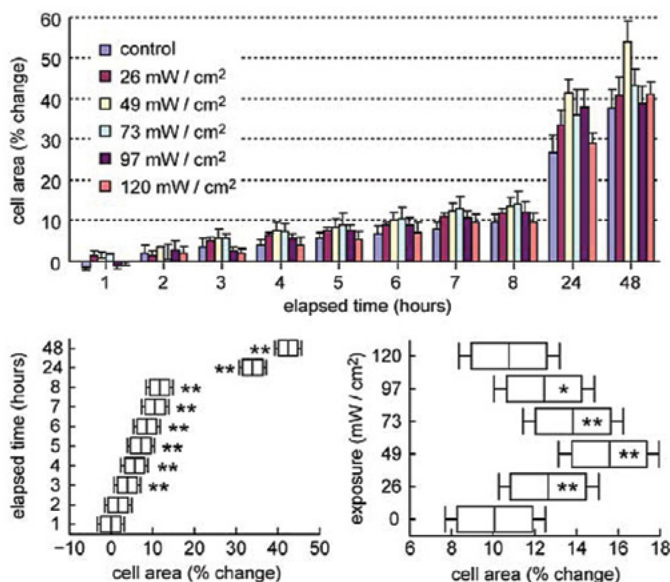


Figure 2: Top panel: cell growth in wound model as a function of time elapsed from wound induction and laser exposure intensity. Vertical bars show % change in cell coverage area averaged across five experiments in which cells were not exposed to laser light, or in which cells were exposed to 26-120 mW/cm² of light during a two minute exposure by varying the laser power from 1.5-7.5 W to give exposure doses from 3.1-14.4 J/cm². Error bars show S.E.M across five experiments. Bottom left: confidence intervals from the two-factor ANOVA analysis demonstrate a significant increase in cell coverage area observed as early as 3 hours after wound induction regardless

of laser exposure (** $p < 0.01$). Horizontal bars show 95% confidence intervals with midline at mean value; error bars show 99% confidence intervals. Bottom right: confidence intervals from the two-factor ANOVA analysis demonstrate a significant increase in cell coverage area for low and moderate levels of laser exposure when compared to no laser exposure (** $p < 0.01$ for 26-73 mW/cm²; * $p < 0.05$ for 97 mW/cm²). No significant increase in cell coverage was observed at the highest exposure level (120 mW/cm²).

Figure 3 shows the results of the second experiment in which exposure durations were varied from 20 sec-15 min at a constant laser output power of 4.5 W to produce an exposure level of 73 mW/cm², resulting in exposure doses from 1.5-66 J/cm². As with changes in exposure level, significant cell recovery was observed within three hours of wound induction regardless of exposure duration, and a wide range of exposure durations appeared to enhance cell growth at all time intervals relative to control experiments in which no laser exposure was applied (figure 3, top panel). These results were confirmed by the results of a two-factor ANOVA (figure 3, lower right), which shows that significant increases in cell growth were observed with 73 mW/cm² exposures having durations of 20 sec-2 min to produce exposure doses of 1.5-8.8 J/cm² ($p < 0.01$). Note that a long exposure of 15 min (65.7 J/cm²) produced a significant decrease in cell growth ($p < 0.05$), suggesting that long exposure to laser light at a moderate level can reverse the benefits of lower exposure doses. A comparison of these results to the mean cell growth measured at various time intervals following wound induction (figure 3, lower left) showed that the 6% increase in cell growth produced by 73 mW/cm² of laser exposure over a 20 sec-2 minute period represented an acceleration of wound healing by approximately two hours within the first eight hours of healing. Furthermore, the two-factor ANOVA analysis did not find any significant interaction between elapsed time and exposure duration despite the significant increases in cell growth across various time intervals and various exposure durations.

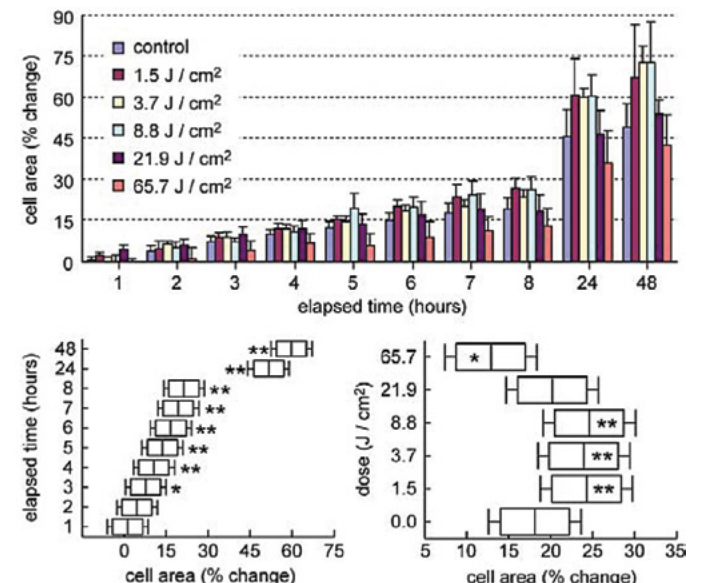


Figure 3: Top panel: cell growth in wound model as a function of time elapsed from wound induction and laser exposure dose. Vertical bars show % change in cell coverage area averaged across five experiments in which cells were not

exposed to laser light, or in which cells were exposed to 73 mW/cm² of light during exposures that varied from 20 sec to 15 min to give exposure doses from 1.5-65.7 J/cm². Error bars show S.E.M across five experiments. *Bottom left*: confidence intervals from the two-factor ANOVA analysis demonstrate a significant increase in cell coverage area observed as early as 3 hours after wound induction regardless of laser exposure (* p < 0.05 for 3 hours, ** p < 0.01 for 4 hours and beyond). *Bottom right*: confidence intervals from the two-factor ANOVA analysis demonstrate a significant increase in cell coverage area for moderate laser exposure doses when compared to no laser exposure (** p < 0.01 for 1.5-8.8 J/cm²). No significant increase in cell coverage was observed at the second highest dose (21.9 J/cm²), and a significant decrease in cell coverage was observed at the highest exposure dose (*p < 0.05 for 65.7 J/cm²).

CONCLUSIONS

Our results confirm the clinical observation that low-level exposure to 980 nm of laser light can accelerate cell growth in a wound healing model. Because our measurements were obtained from an in vitro cell culture model, these results also suggest that the mechanisms involved in the acceleration of cell growth following laser exposure are cellular or molecular in nature. The hypothesis that IR light accelerates healing processes by heating skin and promoting increased blood flow (Dierickx, 2006) could not explain the increased cell growth rates in an in vitro cell culture model. Our measurements suggested that IR exposure produced temperature increases less than 2 °C, and the use of a controlled incubation environment between image acquisition intervals further minimizes the temperature variability in our experiments. Previous researchers have suggested that light exposure increases ATP levels by altering the energetic state of light-sensitive cytochromes within the inner mitochondrial membrane that participate in oxidative phosphorylation (Karu et al., 1995); we are conducting further experiments to examine ATP levels following low-level exposure to 980 nm laser light.

Our results also demonstrate the importance of appropriate supervision of laser light exposure in a clinical setting. In particular, the average cell growth rates formed a non-monotonic function of laser exposure levels (figure 2, lower right) and exposure doses (figure 3, lower right); with peak growth rates at moderate exposures, and reduced benefit at higher exposure intensities and doses. This suggests that excessive light exposure could have potentially damaging effects that negate any initial benefit of light exposure. Therefore the appropriate exposure levels and durations must be selected in order to maximize cell growth rates.

ABOUT THE AUTHORS

Mark Skopin Ph.D. is an Academic Fellow at the University of Maryland School of Medicine in the Shock, Trauma & Anesthesiology Research (STAR) Center. Past research includes Traumatic Brain Injury (TBI); “Studying The Effects Of TBI On Sleep Behavior”; “Investigation Of Brain Injury Induced By TBI And Blood-Brain Barrier (BBB) Disruption”; “The Relationship Of TBI To Spreading Depression, Olfaction, And Sleep Cycles” And The Computational Modeling Of Neural Systems, “Development Of Biological Neural N “Creation Of A MATLAB-XPP Interface To Analysis Parametric Modulation Of Neuronal Models CNS Cell Populations,” Email: mskopin@anes.umm.edu

Dr. Scott C. Molitor is the Associate Professor and Undergraduate Program Director, University of Toledo. He holds a Ph.D., from the Johns Hopkins University School of Medicine and has extensive research and expertise in Auditory Physiology, Models of Traumatic Brain Injury, Cellular Electrophysiology, and Computational Modeling of Neuronal Function. Email: scott.molitor@utoledo.edu

REFERENCES

- Dierickx CC (2006) The role of deep heating for noninvasive skin rejuvenation. *Lasers Surg Med* 38:799-807.
- Hawkins DH, Abrahamse H (2006) The role of laser fluence in cell viability, proliferation, and membrane integrity of wounded human skin fibroblasts following helium-neon laser irradiation. *Lasers Surg Med* 38:74-83.
- Karu T, Pyatibrat L, Kalendo G (1995) Irradiation with He-Ne laser increases ATP level in cells cultivated in vitro. *J Photochem Photobiol B* 27:219-223.
- Mester E, Mester AF, Mester A (1985) The biomedical effects of laser application. *Lasers Surg Med* 5:31-39.