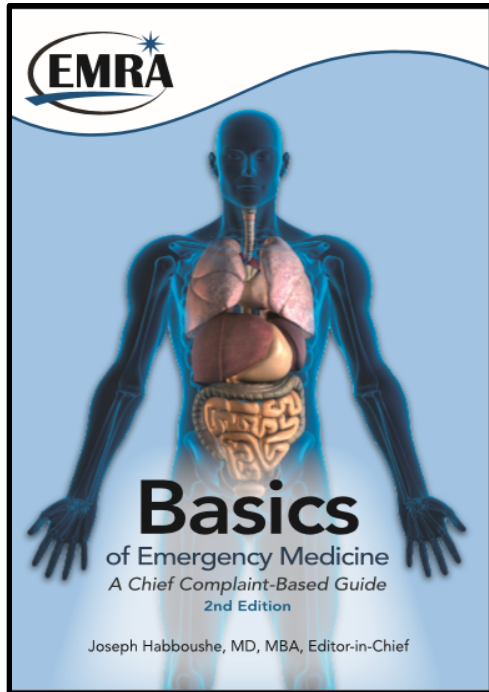




CHEST PAIN

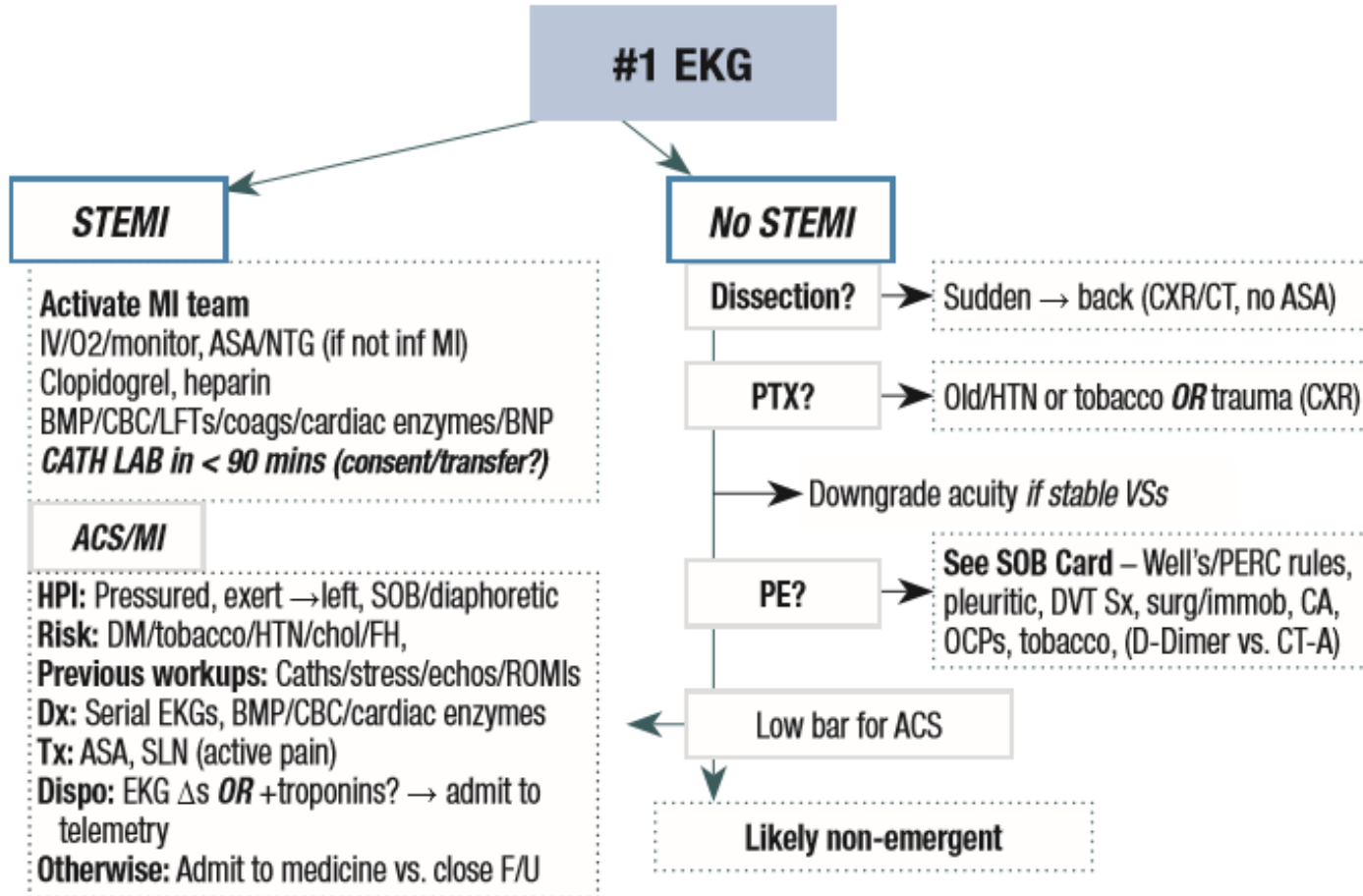


A 55 year old female with diabetes and hypertension presents with left-sided chest pain and nausea for twenty minutes. She is sweaty and appears short of breath...

MD+
CALC



CHEST PAIN



CHEST PAIN

	DISEASE	HISTORY & PHYSICAL EXAM	WORKUP	TREATMENT
Emergent	STEMI/ACI	<i>See above</i>		
	Dissection	HTN, sharp →back	CXR/CT	↓BP, consult surgery
	Pneumothorax	Tobacco, sharp, trauma, tall	CXR , U/S	Chest tube, consult surgery
	PE	<i>(See Shortness of Breath, page 8)</i>	D-Dimer/CT-A	Anticoagulation, (tPA if ↓BP)
	Esophageal rupture	Wretching, EtOH	CXR/abdominal XR	Consult surgery
	Tamponade	Beck's: ↓ heart sounds, ↓BP, +JVD	Echo	Pericardiocentesis
Non-Emergent	Cocaine CP	ACS CP	EKG, troponins	No βB, 2-trop R/O, ASA, benzos
	Pneumonia	Fever/productive cough	CXR, rectal temp	Abx <i>(see Shortness of Breath, page 8)</i>
	Pericarditis	Lying flat, fever?, rub	EKG, echo	NSAIDs
	GERD	Burn, food → throat	GI cocktail	GI cocktail, PPIs
	Musculoskeletal	Reproducible	Exclusion	Pain (CXR R/O PTX)
	Endocarditis	Fever, murmur, IVU	Echo	Abx, consult cardiology

CHEST PAIN

Pearls + Pitfalls

- ACS and PE patients can be sick but not look sick.
- EKGs: Get old for comparison; get serial EKGs.
- ACS concerning if: diaphoresis, vomiting, *right* arm.

Documentation

General: Diaphoresis, presently CP?, tachypnea, BPs in both arms

Heart/Chest: RRR s1/s2, no murmurs/rubs, ↓ heart sounds, no JVD, tender chest wall

Lung: Decreased breath sounds, ronchi, rales, wheezing (with location)