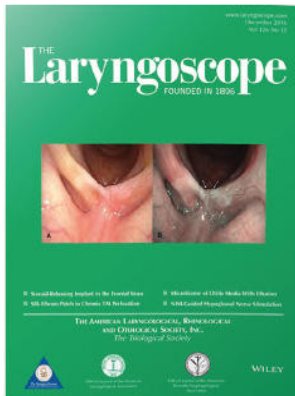



Premiere Publications from The Triological Society

Read all three of our prestigious publications, each offering high-quality content to keep you informed with the latest developments in the field.




THE Laryngoscope FOUNDED IN 1896

Editor-in-Chief: Michael G. Stewart, MD, MPH

The leading source for information in head and neck disorders.

Laryngoscope.com




Laryngoscope Investigative Otolaryngology Open Access

Editor-in-Chief: D. Bradley Welling, MD, PhD, FACS

Rapid dissemination of the science and practice of otolaryngology-head and neck surgery.

InvestigativeOto.com



ENTtoday A publication of the Triological Society



Editor-in-Chief: Alexander Chiu, MD

Must-have timely information that Otolaryngologist-head and neck surgeons can use in daily practice.

Enttoday.org

WILEY

Long-term Sinonasal Outcomes After Endoscopic Skull Base Surgery With Nasoseptal Flap Reconstruction

Charles A. Riley, MD ; Abtin Tabae, MD; Lindsey Conley, MD; Muhamad Amine, MD; Christian P. Soneru, MD ; Vijay K. Anand, MD; Theodore H. Schwartz, MD

Objectives: The utilization of the nasoseptal flap (NSF) in endoscopic anterior skull base surgery (EASB) has resulted in reduced rates of postoperative cerebrospinal fluid leak (CSF). The long-term impact on sinonasal function after surgery remains incompletely defined.

Methods: A consecutive series of patients undergoing EASB with NSF and with at least 3 years follow-up was prospectively evaluated. Patient demographics, pre- and postoperative Sino-nasal Outcome Test-22 (SNOT-22) scores, Lund-Mackay scores (LMS), CSF leak, and sinonasal complications were analyzed.

Results: A total of 46 patients undergoing EASB with NSF met inclusion criteria. The mean follow-up was 67.4 months (range 39–90, standard deviation [SD] 14.2 months). No statistically significant differences were noted between the mean overall pre- (16) and postoperative SNOT-22 scores (18). SNOT-22 scores improved in 27 patients (58.7%), deteriorated in 17 patients (37.0%) and stayed the same in two patients (4.3%). Deterioration in SNOT-22 scores was greater in younger (mean change + 7.2 [SD17.4] vs. older patients –3.4 [SD 7.5], $P = 0.010$). A statistically significant increase in LMS was noted (mean preoperative LMS0.9 vs. mean postoperative LMS 2.2, $P = 0.001$). The LMS decreased in nine patients (19.6%), increased in 22 patients (47.8%), and remained the same in 15 patients (32.6%). One patient (2.2%) developed a postoperative CSF leak following resection of metastatic skull base lesion and was successfully treated with placement of a lumbar drain, Foley catheter balloon, and strict bed rest. One patient (2.2%) developed a postoperative mucocele requiring decompression 3 years after initial surgery.

Conclusion: Whereas long-term sinonasal quality of life is overall improved in the majority of patients following NSF use for EASB, younger patients show higher incidence of deterioration. Increased sinus opacification on imaging is generally noted and may require continued follow-up and management. The incidence of reoperation for symptomatic mucocele formation is low.

Key Words: Endoscopic skull base surgery, sinonasal outcomes, sinonasal outcome test-22, quality of life, lund mackay score, nasoseptal flap.

Level of Evidence: 4

Laryngoscope, 129:1035–1040, 2019

INTRODUCTION

The widespread adoption of the nasoseptal flap (NSF) has had broad-reaching implications on endoscopic anterior skull base (EASB) surgery.¹ Favorable aspects of the NSF include its large surface area, favorable arc of rotation, and robust vascularity via the posterior nasal septal branch of the sphenopalatine artery.² Based on these factors, it has become the workhorse flap, a routine and important component of the multilayered repair for reconstructing anterior skull base defects.^{3,4} Prior to the NSF, cerebrospinal fluid (CSF) leak rates ranged from 5%

to 40%.^{5–8} Current studies suggest CSF leak rates with the NSF range from 0% to 5%.^{9–11}

Complications and morbidity associated with EASB surgery with NSF harvest remain important to consider as normal nasal structures are resected or altered. Transient crusting, nasal obstruction, and a decreased sense of smell are common.^{12,13} Potential long-term complications include permanent hyposmia, sinonasal dysfunction, and delayed mucocele formation.^{14–16} Although short-term outcome data has been examined, the long-term impact of EASB surgery with NSF on sinonasal quality of life (QOL) and radiographic outcomes remains incompletely defined.¹⁷

From the Department of Otolaryngology–Head and Neck Surgery (C.A.R., A.T., M.A., C.P.S., V.K.A.); Department of Radiology (L.C.); and the Department of Neurosurgery (T.H.S.), New York Presbyterian Hospital–Weill Cornell Medicine, New York, New York, U.S.A.

Editor's Note: This Manuscript was accepted for publication on October 4, 2018.

Presented as a poster presentation, American Rhinologic Society, Combined Otolaryngology Spring Meeting, National Harbor, Maryland, U.S.A., April 19–20, 2018.

The authors have no funding, financial relationships, or conflicts of interest to disclose.

Send correspondence to Abtin Tabae, MD, 1305 York Avenue, 5th Floor, New York, NY 10021. E-mail: atabae1@gmail.com

DOI: 10.1002/lary.27637

MATERIALS AND METHODS

Following approval from the Weill Cornell Medical College Institutional Review Board, a prospective case series with chart review was performed for all adult patients (≥ 18 years of age) who underwent endoscopic EASB requiring reconstruction with a NSF by the senior authors (T.H.S., V.K.A.) from September 2010 to December 2014. The surgical technique used for EASB and skull base reconstruction in this series has been previously reported.^{11,18,19} In brief, the skull base repair technique and use

of reconstruction materials is based on multiple factors including the complexity and/or size of the skull base defect, underlying pathology, identification of a high-flow rate of CSF leakage intraoperatively, expected need for postoperative radiation, and patient comorbidity. Study inclusion required completion of a pre- and postoperative 22-item Sino-nasal Outcome Test-22 (SNOT-22) questionnaire and magnetic resonance imaging (MRI) scan with greater than 3 months follow-up after surgery.

Quality of life was assessed with the prospective collection of the validated SNOT-22 QOL questionnaire,²⁰ which was completed during clinic visits. Pre- and postoperative total and subdomain SNOT-22 scores were compared. Sinonasal radiologic findings were assessed with Lund-Macckay scores (LMS) on pre- and postoperative MRIs. Formatting... please wait²¹ To limit interrater error, a single neuroradiologist investigator (L.C.) performed all LMS scoring.

Statistics were performed with the SPSS 20.0 (IBM Corp., Armonk, NY) software. Descriptive data was described with mean and standard deviation (SD). Paired *t* test was used to compare pre- and postoperative overall and subcategorical scores for the SNOT-22 and LMS. The following subdomain categories from the SNOT-22 were analyzed: sleep symptoms, nasal symptoms, otologic/facial pain symptoms, and emotional function.²² Univariate analysis based on gender, median age, and median tumor size was performed. Statistical significance was assessed at 0.05 level.

RESULTS

During the time period investigated from September 2010 to December 2014, a total of 374 endonasal endoscopic procedures were performed. Of these, 165 (44.1%) required nasoseptal flaps. Of those patients, 46 (27.9%) were included in the study based on the availability of pre- and postoperative SNOT-22 data with adequate follow-up and appropriate imaging. Patient and disease demographic data, history of prior treatment and follow-up duration are presented in Table I. A variety of lesions comprised this series, most commonly pituitary adenoma (*n* = 26, 57.8%) and craniopharyngioma (*n* = 9, 20.0%). In this series, a NSF was used in all patients. The harvest site was 23 (50%) right-sided, 16 (34.8%) left-sided, and seven (15.2%) bilateral.²³ Planned lumbar drainage was used in 39 patients (84.8%). The mean follow-up duration for this study was 67.4 months (range 39–90, SD 14.2 months).

The preoperative total and subdomain SNOT-22 scores for this study are presented in Table II. A statistically significant difference following surgery was not observed for the total, otologic/facial pain, or emotional function subdomains SNOT-22 scores. A statistically significant increase in the subdomain scores for nasal symptoms, indicating a deterioration in function, following surgery was noted: the preoperative mean of 3.3 increased to 7.1 postoperatively (*P* < 0.001). There was also statistically significant decrease, or improvement, in the subdomain scores of sleep symptoms following surgery from preoperative mean of 10.3 to 8.3 postoperatively (*P* = 0.01). Overall, 27 patients (58.7%) demonstrated a decrease in total SNOT-22 scores, whereas 17 patients (37.0%) had an increase and two patients (4.3%) had no change, indicating more improvement than deterioration. The changes in the subdomain scores are presented in Table II.

TABLE I.
Patient and Disease Demographics

	Results (N = 46)
Age at surgery	Mean 49.3 (SD 16.3) years
Gender	Female 25 (54%) Male 21 (46%)
Diagnosis	Pituitary adenoma 26 (57.8%) Craniopharyngioma 9 (20.0%) Meningioma 6 (13.3%) Meningoencephalocele 2 (4.4%) Rathke's cleft cyst 1 (2.2%) Metastatic lesion 1 (2.2%) Chordoma 1 (2.2%)
Tumor location	Sella + suprasellar 20 (43.5%) Sellar + suprasellar + cavernous sinus 20 (43.5%) Suprasellar 2 (4.3%) Clivus 2 (4.3%) Anterior cranial fossa 1 (2.2%) Anterior and middle cranial fossa 1 (2.2%)
Tumor size	Maximum tumor dimension: Mean 2.9 (range 1.2–6.2, SD 0.94) cm Tumor volume*: Mean 8.6 (range 0.7–46.7, SD 8.3) cm ³
History of prior treatment	Prior skull base surgery 8 (17.4%) Prior skull base surgery and radiation therapy 5 (10.9%) Prior sinus surgery 1 (2.2%) Prior nasal septum surgery 1 (2.2%)
Tobacco history	No tobacco history 30 (65.2%) Prior history of regular cigarette use 16 (34.8%) Active tobacco history 0 (0%)
Follow-up duration	Office follow-up: mean 67.4 months (range: 39–90 months, SD 14.2 months) Time between surgery and postoperative SNOT-22: mean 8.9 months (range: 2.9–32.2 months, SD 6.4 months) Time between surgery and postoperative MRI: mean 22.4 months (range: 3.0–55.9 months, SD 13.7 months)

*Tumor volume formula: (depth × width × height)/2.
cm = centimeters; SD = standard deviation; SNOT-22 = Sino-nasal Outcome Test-22.

Postoperative Lund-Mackay scores were significant higher compared with preoperative scores, that is, more opacification (2.2 post- vs. 0.9 pre-, *P* < 0.001), combined frontal sinus (0.1 post- vs. 0.0 pre-, *P* = 0.03), combined maxillary sinus (0.3 post- vs. 0.2 pre-, *P* = 0.04), combined anterior ethmoid sinus (0.4 post- vs. 0.1 pre-, *P* < 0.001), and combined posterior ethmoid sinus (0.2 post- vs. 0.1 pre-, *P* = 0.002) scores (Table III). The change in preoperative versus postoperative sphenoid sinus and osteomeatal complex scores did not reach statistical significance. Overall, 22 patients (47.8%) had an increase in total LMS; nine patients (19.6%) had a decrease in total LMS; and 15 patients (32.6%) were unchanged. The changes in the individual sinuses are presented in Table III.

TABLE II.
Comparison of Preoperative and Postoperative Sinonasal Outcome Test-22 Scores

Variable	Preoperative Mean, Range (SD)	Postoperative Mean, Range (SD)	Change in SNOT-22 Scores: Mean (SD), Range, Statistical Significance	Number of Patients With Change in SNOT-22 Scores
Total SNOT-22 score (possible score 0–110)	16.2, 0–60 (12.8)	18.0, 0–73 (16.9)	1.9 (14.3) Range –24 to + 49 <i>P</i> 0.38 (NS)	Increased 17 (37.0%) Decreased 27 (58.7%) Unchanged 2 (4.3%)
Nasal symptoms (possible score 0–40)	3.3, 0–21 (4.6)	7.1, 0–31 (7.1)	3.8 (6.1) Range –10 to + 20 <i>P</i> < 0.001 (S)	Increased 32 (69.6%) Decreased 8 (17.4%) Unchanged 6 (13.0%)
Otologic/ facial pain symptoms (possible score 0–20)	1.5, 0–10 (2.4)	1.8, 0–10 (2.6)	0.2 (2.5) Range –5 to + 8 <i>P</i> 0.54 (NS)	Increased 13 (28.3%) Decreased 13 (28.3%) Unchanged 20 (43.5%)
Sleep symptoms (possible score 0–40)	10.3, 0–27 (7.9)	8.3, 0–34 (9.2)	–2.0 (8.3) Range –18 to + 21 <i>P</i> 0.01(S)	Increased 14 (30.4%) Decreased 29 (63.0%) Unchanged 3 (6.5%)
Emotional function (possible score 0–10)	1.0, 0–8 (1.8)	0.8, 0–6 (1.5)	–0.2 (1.7) Range –6 to + 5 <i>P</i> 0.47(NS)	Increased 9 (19.6%) Decreased 12 (26.1%) Unchanged 25 (54.3%)

N = 46

NS = not significant; S = significant; SD = standard deviation; SNOT-22 = Sino-nasal Outcome Test-22.

Univariate analysis was performed based on patient and disease factors. Differentiation based on a median age of 51.3 years revealed no difference in the total or

subcategory LMS. Statistically significant differences in change in the SNOT-22 were noted following surgery for total score (younger group mean change +7.2 [SD 17.4]

TABLE III.
Comparison of Preoperative and Postoperative Lund-Mackay Scores.

Variable	Preoperative Mean (SD)	Postoperative Mean (SD)	Change in Lund-Mackay Scores: Mean (SD), Range, Statistical Significance	Number of Patients With Change in Lund-Mackay Scores (n = 46)
Total Lund-Mackay score	0.9 (1.3)	2.2 (2.4)	0 (1.5) Range –4 to + 3 <i>P</i> < 0.001 (S)	Increased 22 (47.8%) Decreased 9 (19.6%) Unchanged 15 (32.6%)
Combined frontal sinus	0 (0)	0.1 (0.3)	0.1 (0.4) Range 0 to + 2 <i>P</i> 0.03 (S)	Increased 5 (10.9%) Decreased 0 (0%) Unchanged 41 (89.1%)
Combined maxillary sinus	0.2 (0.4)	0.3 (0.5)	0.2 (0.6) Range –1 to + 2 <i>P</i> 0.04 (S)	Increased 8 (17.4%) Decreased 2 (4.3%) Unchanged 36 (78.3%)
Combined anterior ethmoid sinus	0.1 (0.3)	0.4 (0.5)	0.5 (0.8) Range –1 to + 2 <i>P</i> < 0.001 (S)	Increased 20 (43.5%) Decreased 2 (4.3%) Unchanged 24 (52.2%)
Combined posterior ethmoid sinus	0.1 (0.2)	0.2 (0.5)	0.3 (0.8) Range –1 to + 2 <i>P</i> 0.002 (S)	Increased 11 (23.9%) Decreased 2 (4.3%) Unchanged 33 (71.3%)
Combined sphenoid sinus	0.1 (0.3)	0.1 (0.4)	0.1 (0.8) Range –1 to + 4 <i>P</i> 0.42 (NS)	Increased 5 (10.9%) Decreased 6 (13.0%) Unchanged 35 (76.1%)
Combined osteomeatal complex	0 (0)	0 (0.3)	0.1 (0.4) Range 0 to + 2 <i>P</i> 0.16 (NS)	Increased 2 (4.3%) Decreased 0 (0%) Unchanged 44 (95.7%)

The left and right scores were combined for the specific sinuses (e.g., "total frontal sinus" = combined scores of left and right frontal sinuses). Possible range of scores for the total Lund-Mackay score is 0–24. The possible range of scores for the combined left and right for individual sinuses is 0–4.

NS = nonsignificant; SD = standard deviation.

vs. older group -3.4 [SD 7.5], $P = 0.010$), nasal subdomain scores (younger group $+6.0$ [SD 6.7] vs. older $+1.7$ [SD 4.5], $P = 0.014$) and otologic subdomain scores (younger group $+1.2$ [SD 2.8] vs. older -0.8 [SD 1.6], $P = 0.005$). There were no significant differences in other SNOT-22 subdomains. Comparison of radiographic and SNOT-22 outcomes failed to reveal any significant differences based on gender, history of tobacco use, tumor type (differentiated based on pituitary adenoma vs. other tumor types), tumor location, or tumor size (differentiated based on median tumor volume size of 6.3 cm^3 , $n = 44$, meningoencephalocele patients excluded).

Comparison between primary ($n = 33$) and revision patients ($n = 13$) was performed with regard to LMS and SNOT-22 outcomes. There was not a statistically significant difference in preoperative LMS, postoperative LMS, or change in LMS between the two cohorts. Patients undergoing revision surgery were noted to have a statistically higher preoperative total SNOT-22 score (mean 22.6, SD 16.1 vs. 13.6, SD 10.5, $P = 0.015$) and higher postoperative SNOT-22 score (mean 26.2, SD 19.5 vs. 14.8, SD 14.9, $P = 0.02$). The change in total SNOT-22 scores after surgery was not significantly different. Analysis of SNOT-22 subdomains revealed that patients undergoing revision surgery were noted to have a statistically higher preoperative sleep subdomain score (mean 13.5, SD 8.4 vs. 9.0, SD 7.5, $P = 0.08$) and higher postoperative SNOT-22 score (mean 26.2, SD 19.5 vs. 14.8, SD 14.9, $P = 0.02$). Similarly, patients undergoing revision surgery were noted to have a significantly higher preoperative emotional subdomain score (mean 1.9, SD 2.2 vs. 0.7, SD 1.5, $P = 0.03$) and higher postoperative SNOT-22 score (mean 1.8, SD 1.9 vs. 0.5, SD 1.1, $P = 0.01$). Change in sleep and emotional subdomain scores were not statistically significant, nor were the preoperative, postoperative, or change in otologic/facial subdomain scores.

One patient (2.2%) developed a postoperative CSF leak following resection of metastatic skull base lesion and was successfully repaired following 5 days of conservative measures, which included intranasal placement of a Foley catheter to support the skull base repair site, lumbar drainage and bed rest. One patient (2.2%) developed a postoperative mucocele requiring decompression 3 years after initial surgery.

DISCUSSION

Endoscopic skull base surgery has evolved rapidly with recent technological and surgical advances. With the widespread implementation of the NSF, complex skull base reconstruction has become more successful following the removal of large tumors or tumors that involve critical neurovascular structures.¹⁻⁴ Yet, the long-term impact of EASB with NSF on sinonasal QOL and radiographic outcomes remains incompletely defined. Although several studies have looked at components of this question, to our knowledge this is the first prospective study to examine long-term overall and subdomain SNOT-22 and LMS scores in patients undergoing EASB surgery with NSF that compared pre- and postoperative scores in the same patients.

Several studies have assessed the QOL outcomes following EASB in general. Early work found that short-term postoperative QOL was superior in patients who had endoscopic resections of skull base tumors when compared to those who underwent a subcranial approach.²⁴ Sinonasal QOL has been shown to deteriorate in the early postoperative period (3–12 weeks after surgery) following EASB^{25,26} with return to baseline 3 to 6 months after surgery. Increases in intranasal cross-sectional area do not appear to affect sinonasal QOL.²⁷

Additional research has focused on QOL outcomes in patients undergoing endoscopic resection of sinonasal tumors without NSF. Harrow et al. reported that mean SNOT-20 scores as well as scores for questions corresponding to the rhinologic and ear/facial subdomains were improved at 3 and 6 months after surgery relative to preoperative levels but that the improvement was only found in patients with benign tumors.²⁸ In looking at long-term outcomes, the significant improvements for patients with benign tumors seen 6 months after surgery were not sustained at 1 or 2 years after surgery, although patients with malignant tumors did have improved psychological and sleep subdomain scores at these later time points.²⁹ Glicksman et al. found contradictory results. These authors followed 145 patients who underwent endoscopic resection of benign and malignant sinonasal tumors for 2 years postoperatively and found that SNOT-22 scores were significantly improved from baseline at 3 months and that the improvement was sustained for the 2-year follow-up period.³⁰ However, QOL scores were worse at all time points for patients with malignant disease relative to those with benign tumors.

The literature examining sinonasal QOL scores with NSF similarly suggest that the short-term outcome scores worsen transiently and then return to baseline, although the data is conflicting.³¹ With regard to endoscopic transnasal pituitary surgery, Chaaban et al. found that University of Pennsylvania Smell Identification Test scores were not significantly different and that utilization of the NSF for reconstruction did not adversely affect postoperative scores.³² Correspondingly, Jalessi et al. demonstrated that in patients with pituitary adenomas undergoing endoscopic endonasal transsphenoidal surgery, NSF harvest resulted in a transient decrease in QOL that returned to baseline within 3 months. Overall, there was significant improvement in SNOT-22 scores at 12 months after surgery compared to preoperative data.³³

Examining QOL in extended endonasal approaches with NSF reconstruction for benign skull base tumors, Georgalas et al. demonstrated limited impact, which was mostly related to headache and reduced olfaction utilizing the Rhinosinusitis Outcome Measure-31 questionnaire.³⁴ Harvey et al. found that sinonasal QOL was more closely related to skull base pathology compared to NSF use, suggesting that loss of sinonasal function from radiation or resection of functional areas including olfactory mucosa played a more important role.³⁵ In a recent systematic review examining objective sinonasal outcomes including olfaction, mucociliary clearance, and nasal airflow, Greig et al. identified 10 articles and concluded that NSF elevation led to impairment in olfactory function.

The authors offer the option to avoid routine NSF elevation in sellar and parasellar procedures—and if a NSF is utilized, that the donor site defect reconstruction be considered.³⁶ Lacking from these studies is a long-term, prospective perspective of sinonasal QOL following NSF harvest in EASB surgery.

In this study, there is a nonsignificant increase in mean total SNOT-22 score at nearly 1 year after surgery. Otolgic/ facial pain and emotional function scores were also not significant at postoperative query. Nasal symptom subdomain scores were significantly increased, whereas sleep subdomain scores significantly decreased. Additionally, in this study there is a limited association between NSF for EASB surgery and sinonasal mucosal thickening as determined by LMS on postoperative MRIs performed, on average, nearly 2 years after surgery. The significance of this finding is unclear because there was a seemingly clinically insignificant change in LMS from 0.9 to 2.2 in this cohort. Previous studies have examined the average LMS in otherwise healthy individuals and have concluded that the average patient has an incidental LMS of 3.³⁷ Continued outpatient nasal hygiene and debridement may be vital for these patients.

Importantly, we routinely do not resect the middle turbinate during these surgeries. Instead, the middle turbinate is only resected if deemed critical for the approach to and the resection of the skull base pathology. In this study, no middle turbinates were resected. Previously, Deconde et al. noted a higher rate of mucosal thickening of anterior ethmoid and maxillary sinuses in patients with partially resected middle turbinate on the 6-month postoperative MRI following an endoscopic skull base approach.³⁸ This study appears to corroborate those findings and supports middle turbinate preservation whenever feasible.

Complications are associated with the use of the NSF during endoscopic skull base surgery. Mucoceles can arise months to years following surgery and can be associated with significant intracranial complications, including meningitis. In this study, there was a single occurrence of mucocele formation that was discovered on routine MRI follow-up 3 years after the initial skull base surgery, yielding a mucocele formation rate of 2.2% in this series, which is consistent with the published literature. Such low rates are a result of meticulous removal of all sphenoid mucosa prior to flap placement. Bleier et al. demonstrated a mucocele formation rate of 4% within 9 months of surgery.³⁹ Another study examining 121 patients with NSF placement between 2008 and 2013 did not demonstrate any mucocele formation.⁴⁰ However, the authors report a complication rate higher than previously described in the literature, with complications relating to NSF harvest in 33 patients (27%). The majority of complications were related to the septal donor site, which included septal perforation, cartilage necrosis, and prolonged crusting, as well as intraoperative injury to the pedicle in four patients and recurrent or persistent CSF leak in seven patients. There was one instance of CSF leak in this series for an overall postoperative CSF leak rate of 2.2% in this study. Nasoseptal flap placement in EASB surgery has resulted in a significant decrease in

postoperative CSF leak, with the current literature demonstrating a leak rate around 5%.^{10,11}

Limitations of this study include the modest sample size and lack of a control group. Furthermore, the LMS is an imperfect system to attempt to characterize sinonasal dysfunction and does not necessarily correlate to disease severity. Additionally, SNOT-22 scores are based on patient interpretation of the past 2 weeks of symptoms. With an average duration of 9 months between surgery and postoperative SNOT-22 collection, other variables may affect this score, including rhinitis and sinusitis. Our study and follow-up methodologies do not allow for capturing the occurrence of other rhinologic issues because the long-term tumor follow-up is performed by the neurosurgery team. Future directions may include a larger case series with a longer duration of radiographic follow up, assessment of other rhinologic outcomes including clinical occurrence of sinusitis events and objective measurement of olfactory function.

CONCLUSION

In this prospective case series examining adult patients undergoing EASB surgery with NSF reconstruction, although there was no overall change from pre- to postoperative SNOT-22 scores, younger patients showed a higher rate of deterioration. Lund-Mackay scores showed a statistically significant increase at nearly 2 years after surgery indicating some degree of long-term mucosal inflammation. This suggests that although there is some minor disruption of the sinonasal anatomy and physiology resulting in worsening MRI findings, these patients do not complain of worsening sinonasal QOL. Major complications such as CSF leak and mucocele formation were rare, supporting both the overall safety of EASB with NSF and the need for long-term postoperative care.

BIBLIOGRAPHY

1. Hadad G, Bassagasteguy L, Carrau RL, et al. A novel reconstructive technique after endoscopic expanded endonasal approaches: Vascular pedicle nasoseptal flap. *Laryngoscope* 2006;116:1882–1886.
2. Pinheiro-Neto CD, Prevedello DM, Carrau RL, et al. Improving the design of the pedicled nasoseptal flap for skull base reconstruction: a radio-anatomic study. *Laryngoscope* 2007;117:1560–1569.
3. Raza SM, Schwartz TH. Multi-layer reconstruction during endoscopic endonasal surgery: how much is necessary? *World Neurosurg* 2015;83:138–139.
4. McCool ED, Anand VK, Singh A, Nyquist GG, Schaberg MR, Schwartz TH. Long-term effectiveness of a reconstructive protocol using the nasoseptal flap after endoscopic skull base surgery. *World Neurosurg* 2014;81:136–143.
5. Harvey RJ, Parmar P, Sacks R, Zanation AM. Endoscopic skull base reconstruction of large dural defects: a systematic review of published evidence. *Laryngoscope* 2012;122:452–459.
6. Dusick JR, Esposito F, Kelly DF, et al. The extended direct endonasal transsphenoidal approach for nonadenomatous suprasellar tumors. *J Neurosurg* 2005;102:832–841.
7. Dehdashti AR, Ganna A, Witterick I, Gentili F. Expanded endoscopic endonasal approach for anterior cranial base and suprasellar lesions: Indications and limitations. *Neurosurgery* 2009;64:677–87; discussion 687.
8. Kitano M, Taneda M. Subdural patch graft technique for watertight closure of large dural defects in extended transsphenoidal surgery. *Neurosurgery* 2004;54:653–660; discussion 660.
9. Thorp BD, Sreenath SB, Ebert CS, Zanation AM. Endoscopic skull base reconstruction: a review and clinical case series of 152 vascularized flaps used for surgical skull base defects in the setting of intraoperative cerebrospinal fluid leak. *Neurosurg Focus* 2014;37:E4.
10. Bedrosian JC, Anand VK, Schwartz TH. The endoscopic endonasal approach to repair of iatrogenic and noniatrogenic cerebrospinal fluid leaks and encephaloceles of the anterior cranial fossa. *World Neurosurg* 2014;82(suppl):S86–S94.

11. Patel KS, Komotar RJ, Szentirmai O, et al. Case-specific protocol to reduce cerebrospinal fluid leakage after endonasal endoscopic surgery. *J Neurosurg* 2013;119:661–668.
12. Soudry E, Psaltis AJ, Lee KH, Vaezafshar R, Nayak JV, Hwang PH. Complications associated with the pedicled nasoseptal flap for skull base reconstruction. *Laryngoscope* 2015;125:80–85.
13. Upadhyay S, Buohliqah L, Dolci RLL, Otto BA, Prevedello DM, Carrua RL. Periodic olfactory assessment in patients undergoing skull base surgery with preservation of the olfactory strip. *Laryngoscope* 2017;127:1970–1975.
14. Greig SR, Cooper TJ, Sommer DD, Nair S, Wright ED. Objective sinonasal functional outcomes in endoscopic anterior skull-base surgery: an evidence-based review with recommendations. *Int Forum Allergy Rhinol* 2016;6:1040–1046.
15. Vaezafshar R, Hwang PH, Harsh G, Turner JH. Mucocele formation under pedicled nasoseptal flap. *Am J Otolaryngol* 2012;33:634–636.
16. Husain Q, Sanghvi S, Kovalerchik O, et al. Assessment of mucocele formation after endoscopic nasoseptal flap reconstruction of skull base defects. *Allergy Rhinol (Providence)* 2013;4:e27–e31.
17. McCoul ED, Anand VK, Bedrosian JC, Schwartz TH. Endoscopic skull base surgery and its impact on sinonasal-related quality of life. *Int Forum Allergy Rhinol* 2012;2:174–181.
18. Garcia-Navarro V, Anand VK, Schwartz TH. Gasket seal closure for extended endonasal endoscopic skull base surgery: efficacy in a large case series. *World Neurosurg* 2013;80:563–568.
19. Tabaee A, Anand VK, Brown SM, Lin JW, Schwartz TH. Algorithm for reconstruction after endoscopic pituitary and skull base surgery. *Laryngoscope*. 2007;117:1133–1137.
20. Piccirillo JF, Merritt MG, Richards ML. Psychometric and clinimetric validity of the 20-item Sino-nasal Outcome Test (SNOT-20). *Otolaryngol Head Neck Surg* 2002;126:41–47.
21. Lund VJ, Mackay IS. Staging in rhinosinusitis. *Rhinology* 1993;31:183–184.
22. Feng AL, Wesely NC, Hoehle LP, et al. A validated model for the 22-item Sino-nasal Outcome Test subdomain structure in chronic rhinosinusitis. *Int Forum Allergy Rhinol* 2017;7:1140–1148.
23. Nyquist GG, Anand VK, Singh A, Schwartz TH. Janus flap: bilateral nasoseptal flaps for anterior skull base reconstruction. *Otolaryngol Head Neck Surg* 2010;142:327–331.
24. Abergel A, Cavel O, Margalit N, Fliss DM, Gil Z. Comparison of quality of life after transnasal endoscopic vs open skull base tumor resection. *Arch Otolaryngol Head Neck Surg* 2012;138:142–147.
25. Balaker AE, Bergsneider M, Martin NA, Wang MB. Evolution of sinonasal symptoms following endoscopic anterior skull base surgery. *Skull Base* 2010;20:245–251.
26. McCoul ED, Bedrosian JC, Akselrod O, Anand VK, Schwartz TH. Preservation of multidimensional quality of life after endoscopic pituitary adenoma resection. *J Neurosurg* 2015;123:813–820.
27. McCoul ED, Patel AS, Bedrosian JC, Anand VK, Schwartz TH. Intranasal cross-sectional area and quality of life changes following endoscopic transsphenoidal skull base surgery. *Int Forum Allergy Rhinol* 2015;5:1124–1128.
28. Harrow BR, Batra PS. Sinonasal quality of life outcomes after minimally invasive resection of sinonasal and skull-base tumors. *Int Forum Allergy Rhinol* 2013;3:1013–1020.
29. Derousseau T, Manjunath L, Harrow B, Zhang S, Batra PS. Long-term changes in quality of life after endoscopic resection of sinonasal and skull-base tumors. *Int Forum Allergy Rhinol* 2015;5:1129–1135.
30. Glicksman JT, Parasher AK, Brooks SG, et al. Sinonasal quality of life after endoscopic resection of malignant sinonasal and skull base tumors. *Laryngoscope* 2018;128:789–793.
31. Pant H, Bhatki AM, Snyderman CH, et al. Quality of life following endonasal skull base surgery. *Skull Base* 2010;20:35–40.
32. Chaaban MR, Chaudhry AL, Riley KO, Woodworth BA. Objective assessment of olfaction after transsphenoidal pituitary surgery. *Am J Rhinol Allergy* 2015;29:365–368.
33. Jaleesi M, Jahanbakhshi A, Amini E, Kamrava SK, Farhadi M. Impact of nasoseptal flap elevation on sinonasal quality of life in endoscopic endonasal approach to pituitary adenomas. *Eur Arch Otorhinolaryngol* 2016;273:1199–1205.
34. Georgalas C, Badloe R, van Furth W, Reinartz S, Fokkens WJ. Quality of life in extended endonasal approaches for skull base tumours. *Rhinology* 2012;50:255–261.
35. Harvey RJ, Malek J, Winder M, et al. Sinonasal morbidity following tumour resection with and without nasoseptal flap reconstruction. *Rhinology* 2015;53:122–128.
36. Greig SR, Cooper TJ, Sommer DD, Nair S, Wright ED. Objective sinonasal functional outcomes in endoscopic anterior skull-base surgery: an evidence-based review with recommendations. *Int Forum Allergy Rhinol* 2016;6:1040–1046.
37. Ashraf N, Bhattacharyya N. Determination of the “incidental” Lund score for the staging of chronic rhinosinusitis. *Otolaryngol Head Neck Surg* 2001;125:483–486.
38. Deconde AS, Vira D, Thompson CF, Wang MB, Bergsneider M, Suh JD. Radiologic assessment of the paranasal sinuses after endoscopic skull base surgery. *J Neurol Surg B Skull Base* 2013;74:351–357.
39. Bleier BS, Wang EW, Vandergrift WA, Schlosser RJ. Mucocele rate after endoscopic skull base reconstruction using vascularized pedicled flaps. *Am J Rhinol Allergy* 2011;25:186–187.
40. Soudry E, Psaltis AJ, Lee KH, Vaezafshar R, Nayak JV, Hwang PH. Complications associated with the pedicled nasoseptal flap for skull base reconstruction. *Laryngoscope* 2015;125:80–85.