

Shoulder Mobility Deficits

ICD-9-CM codes: 726.0 Adhesive capsulitis of the shoulder

ICF codes: Activities and Participation Domain codes:

d4452 Reaching (Using the hands and arms to extend outwards and touch and grasp something, such as when reaching across a table or desk for a book.)

Body Structure code: **s7201** Joints of shoulder region

Body Functions code: **b7100** Mobility of a single joint

Common Historical Findings

Lateral shoulder pain - worsens with positions or activities which put stretch on the glenohumeral joint

Progresses to stiffness

Gradual, usually insidious, onset of symptoms

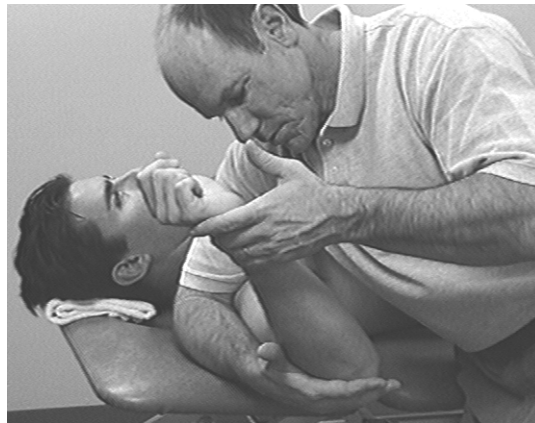
Common Impairment Findings - Related to the Reported Activity Limitation or Participation Restrictions:

ROM limitations - external rotation and abduction are most limited, flexion and internal rotation are least limited

Pain at end ranges--some motions are more painful than others (external rotation with abduction is typically the most painful)

Limited glenohumeral accessory movements

Physical Examination Procedures:



Glenohumeral External Rotation ROM Measurement

Performance Cues:

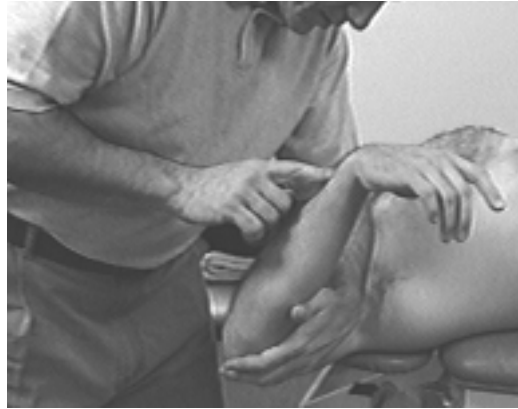Remember that glenohumeral ROM is different than shoulder ROM (shoulder ROM is the sum of glenohumeral and scapular ROM)

Stand in patient's axillary region

Stabilize scapula with forearm

Be precise with stabilization of humeral abduction (to 90 degrees if possible) and horizontal abduction (maintain 0 degrees)

If glenohumeral external rotation ROM is greater at 90 degrees of abduction than at 45 degrees of abduction, suspect a muscle flexibility deficit of the subscapularis
Normal glenohumeral external rotation ROM is 90 degrees



Glenohumeral Internal Rotation ROM Measurement

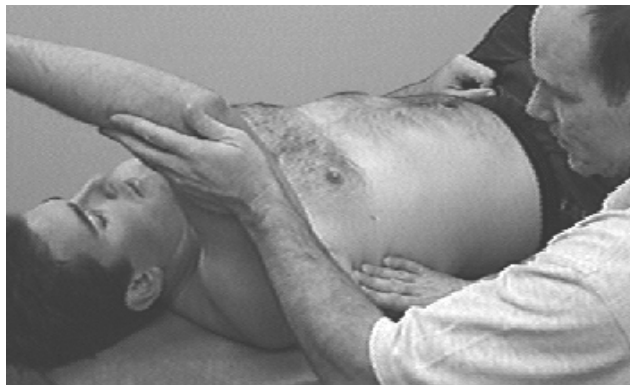Performance Cues:

Stand above the patient

Stabilize scapula in neutral - use forearm to prevent protraction

Be precise with humeral abduction (90 degrees if possible) and horizontal abduction (maintain 0 degrees)

Normal is 60 degrees of isolated glenohumeral internal rotation ROM

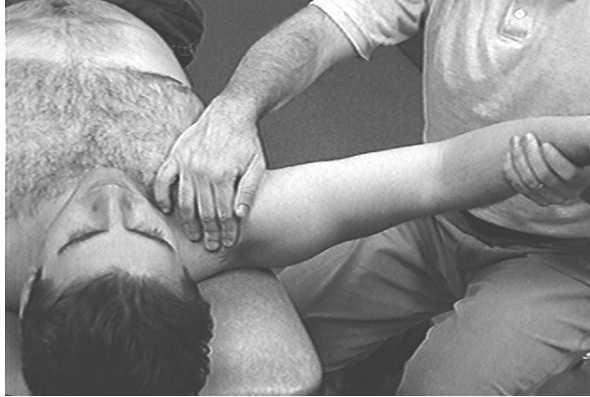

Glenohumeral Flexion ROM Measurement

Performance Cues:

Stabilize scapula - maintain lateral scapular border in a position that is parallel to the tabletop

Normal is 120 degrees of isolated glenohumeral flexion



Glenohumeral Abduction ROM Measurement

Performance Cues:

Glenohumeral (GH) abduction is difficult to assess in patients with adhesive capsulitis because GH abduction requires GH external rotation

Externally rotate humerus to the maximum of pain free motion - then abduct to limitation. (Notate both: e.g., 70° of GH abduction with GH E/R at 30°)

Stabilize scapular to prevent compensatory scapular elevation

Normal is 120 degrees of isolated GH abduction (at 90 degrees of GH E/R)

Shoulder Mobility Deficits: Description, Etiology, Stages, and Intervention Strategies

The below description is consistent with descriptions of clinical patterns associated with shoulder **Adhesive Capsulitis** the vernacular term “**Frozen Shoulder**”

Description: Insidious onset of progressive stiffness and pain of the shoulder

Etiology: The cause of this disorder is presumed to be due to repeated inflammatory reactions in the glenohumeral capsule and synovium, which lead to a thickened, fibrotic and inextensible glenohumeral joint capsule. The altered scapular and glenohumeral joint mechanics due to the glenohumeral capsular restrictions often lead to abnormal stress and subsequent inflammation of the rotator cuff tendons and subacromial bursa

Acute Stage / Severe Condition: Physical Examinations Findings (Key Impairments)

ICF Body Functions codes: **b7100.3** SEVERE impairments of mobility of a single joint

- Excessive scapular protraction
- Excessive scapulothoracic joint motion – a common characteristic is excessive scapular elevation with the scapular upward rotation that normally accompanies overhead activities
- Restricted active ROM – lateral rotation and abduction are commonly the most limited if overhead reaching is the reported functional limitation. Medial rotation is commonly limited if hand behind back movements are the reported functional limitation.

- Isolated glenohumeral motions are considerably limited – typically about 50% of normal (Normal glenohumeral PROM is 120° of flexion, 120° of abduction, 90° of lateral rotation and 70° of medial rotation when measured at 90° of glenohumeral abduction)
- Glenohumeral accessory movements and joint play movements are also considerable limited – especially humeral inferior, posterior and anterior glides
- Symptoms are worst with end-range positions that stretch the capsule
- Rotator cuff muscles may weak and painful due to the tension transmitted to an inflamed joint capsule by contracting musculotendinous units that attach to the capsule
- Pain around joint capsule (near axilla)

Sub Acute / Moderate Condition: Physical Examinations Findings (Key Impairments)

ICF Body Functions codes: **b7100.2** MODERATE impairments of mobility of a single joint

As above with the following differences:

- Resisted Tests are strong and relatively painless when the glenohumeral joint positioned in midrange (thus lessening tension on the capsule)

Now (when less acute) examine the patient for common coexisting upper quadrant impairments. For example:

- Segmental movement abnormalities cervical and upper thoracic spine
- Limited glenohumeral physiologic and accessory movements
- Muscle flexibility deficits – especially subscapularis, infraspinatus, pectoralis minor, pectoralis major, latissimus dorsi, and teres major myofascia
- Nerve mobility deficits – especially median, radial, and ulnar nerves in the common thoracic outlet entrapment areas
- Weak scapular upward rotator muscles – commonly lower trapezius, middle trapezius, and serratus anterior
- Excessive scapular elevation, abduction, downward rotation or winging with overhead reaching

Settled Stage / Mild Condition: Physical Examinations Findings (Key Impairments)

ICF Body Functions codes: **b7100.1** MILD impairments of mobility of a single joint

As above with the following differences:

- Pain with repetitive activities of the shoulder especially at end range
- Painful only with overpressures at end ranges

Intervention Approaches / Strategies

Acute Stage / Severe Condition

Goals: Prevent movement induced inflammatory reactions

Avoid muscle guarding

Painfree with daily activities that use shoulder within available range

Painfree sleep

- Physical Agents:
 - Phonophoresis/iontophoresis or pulsed ultrasound to assist in reducing inflammation
 - Ice and/or TENS for relief of acute pain as well as to reduce muscle guarding
- External Devices (Taping/Splinting/Orthotics)
 - Fit patient with a sling if pain relief requires temporary use of an external device
- Therapeutic Exercises
 - Painfree AROM or passive ROM exercises
 - Pendulum (Codman's) exercises
- Re-injury Prevention Instruction
 - Temporarily limit end range motions or stretches, overhead or behind the back activities that aggravate the patient's condition

Sub Acute Stage / Moderate Condition

Goals: Improve glenohumeral ROM

Improve scapulohumeral rhythm

Prevent re-injury to the joint capsule

Restore strength of the muscles around shoulder and scapula

- Physical Agents:
 - May use ultrasound to the joint capsule prior to active or passive stretching procedures/exercises
- Manual Therapy
 - Soft tissue mobilization to adaptive shortened myofascia
 - Joint mobilization to restricted accessory and joint play motions
- Therapeutic Exercises
 - Stretching exercises to enhance carryover of manual stretching procedures
 - Strengthening exercises to weak scapular depressors, scapular upward rotators, and rotator cuff motions

- Neuromuscular Reeducation
Facilitate neutral thoracic cage, scapular position, and shoulder proprioception
- Ergonomic Instruction:
Promote efficient, painfree, motor control of the trunk, scapulae and arm with overhead activities.
Modify activities to prevent overuse and re-injury

Settled Stage / Mild Condition

Goals: Normalize glenohumeral ROM
Normalize upper quarter posture, muscle flexibility and muscle strength
Progress activity tolerance

- Approaches/ Strategies listed above
- Manual Therapy
Increase intensity and duration of soft tissue mobilization and myofascial stretching to the maximal tolerable level
Increase intensity and duration of joint mobilization procedures to the maximal tolerable
- Therapeutic Exercises
Maximize muscle performance of the relevant trunk, scapulae, shoulder flexion and shoulder girdle muscles required to perform the desired occupational or recreational activities.
- Ergonomic Instruction: as above
Add job or sport specific training

Intervention for High Performance / High Demand Functioning in Workers and Athletes

Goal: Return to desired occupational or sport activities

- Therapeutic Exercises
Progress exercises focusing on job/sport specific training program based on individual needs of patient.

Selected References

- Deyle GD, Bang MD. Examination and treatment of the shoulder. *Orthopaedic Physical Therapy Clinics of North America*. 1999;8:83-115.
- Gross J, Fetto J, Rosen E. *Musculoskeletal Examination*. Blackwell Science, 1996.
- Hannifan JA, Chiaia TA. Adhesive capsulitis: a treatment approach. *Clinical Orthop Rel Res*. 2000; 372:95-109.
- Loyd JA. Adhesive capsulitis of the shoulder, diagnosis and treatment. *South Medical Journal*. 1993;76:879-883.
- Neviaser JS. Adhesive capsulitis and the stiff and painful shoulder. *Orthop Clin of North Am*. 1980;11:327-333.
- Nicholson GG. The effects of passive joint mobilization on pain and hypomobility associated with adhesive capsulitis of the shoulder. *J Orthop Sports Phys Ther*. 1985; 6(4): 238-246.
- Placzek J, Roubal P, Freeman C, et al. Long term effectiveness of translational manipulation for adhesive capsulitis. *Clin Orthop and Rel Res*. 1998;356:181-191.
- Rizk TE, Christopher RP, Pinals RS, et al. Adhesive capsulitis (frozen shoulder): a new approach to its management. *Arch Phys Med Rehabil*. 1983;64:29-33.
- Roubal PJ, Dobitt D, Placzek JD. Glenohumeral gliding manipulation following interscalene brachial plexus block in patients with adhesive capsulitis. *J Orthop Sports Phys Ther*. 1996;24:66-77.
- Tomberlin J, Saunders D. *Evaluation, Treatment, and Prevention of Musculoskeletal Disorders*, 3rd ed., Vol. 2, (Extremities). Educational Opportunities, 1994.
- Vermeulen HM, Oberman WR, et. al. End-range mobilization techniques in adhesive capsulitis of the shoulder joint: a multiple subject case report. *Phys Ther*. 2000;80:1204-1213.
- Wadsworth T. Frozen shoulder. *Phys Ther*. 1986;66:1878-83.

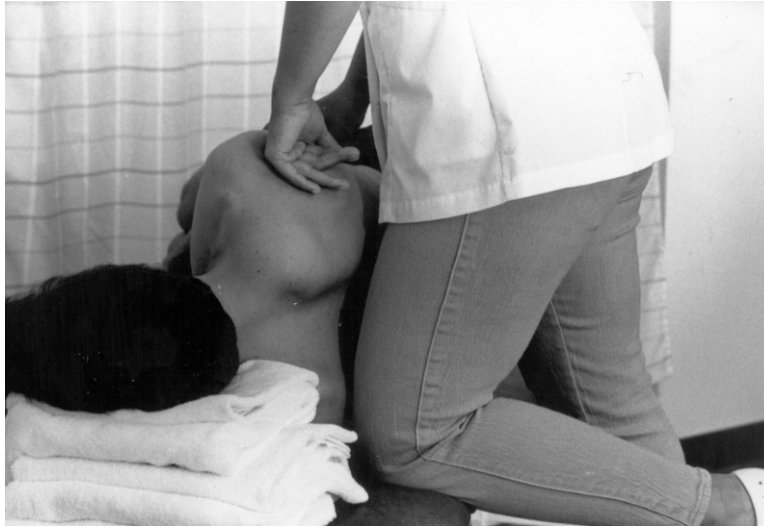SHOULDER MANUAL INTERVENTIONS

Patient Problem: LIMITED HUMERAL INTERNAL ROTATION

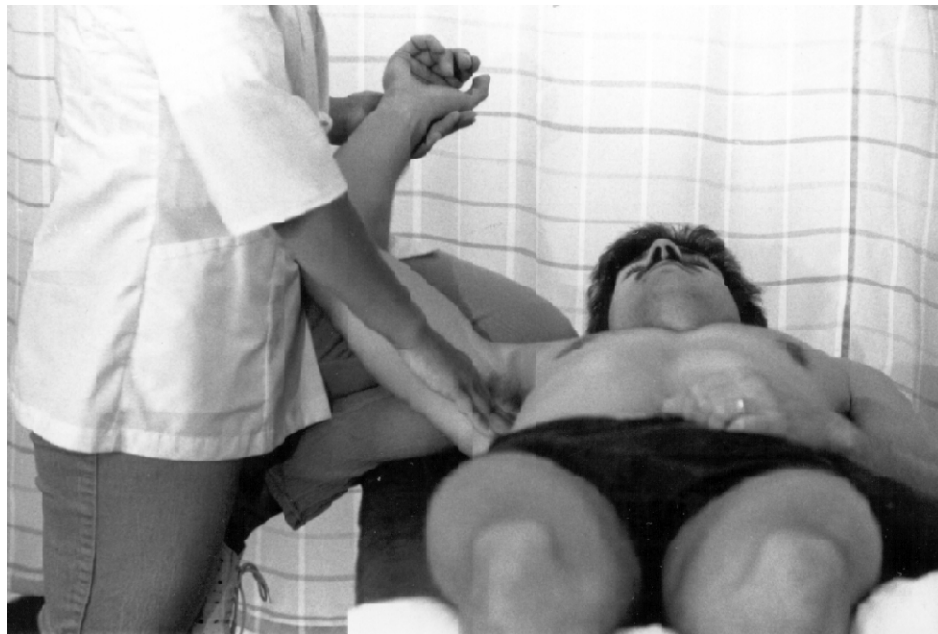- ST MOB: Infraspinatus/Teres Minor/Posterior Deltoid
- JNT MOB: Posterior Glide (loose packed position)
 Posterior Glide (combined movements)
 Distraction
- RE-ED: Extension/Adduction/Internal Rotation PNF pattern (emphasize traction +
 rotation)
 Contract/Relax to glenohumeral external rotators
- MWM: Hand-Behind Back Maneuvers

Patient Problem: LIMITED HUMERAL EXTERNAL ROTATION

- ST MOB: Pectoralis Minor
 Subscapularis
- JNT MOB: Inferior Glide
 Posterior Glide
 Anterior Glide
- RE-ED: Contract/Relax of Extension/Adduction/Internal Rotation PNF pattern (emphasize
 spiral/ diagonal)
 Flexion/Abduction/External Rotation PNF pattern (facilitate movement/traction)
- MWM: Arm Overhead Maneuvers

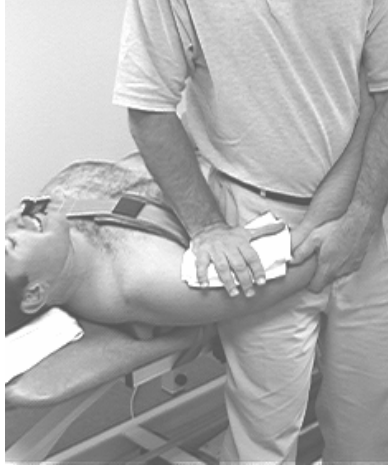

Infraspinatus
Soft Tissue Mobilization



Subscapularis
Soft Tissue Mobilization

Impairment: Limited Shoulder Hand Behind Back Motions
Limited Glenohumeral Internal Rotation
Limited Humeral Posterior Glide

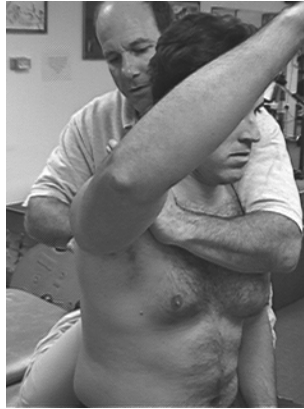

Humeral Posterior Glide

Cues: Position the patient supine with a wedge under the spine of the scapula (not under the glenohumeral joint)
A strap is handy to fixate the upper thorax and scapula - especially if you plan to add the combined movement of humeral distraction
Hug the arm
Use a “flat” hand and padding (folded sheet) to prevent irritation of the anterior humeral/bicipital groove area
Consider adding combined movements of humeral distraction, abduction, and internal rotation as well as cervical sidebending prior to the posterior glide

The following reference provides additional information regarding this procedure:
Freddy Kaltenborn PT: Manual Mobilization of the Extremity Joints, p. 114, 1989

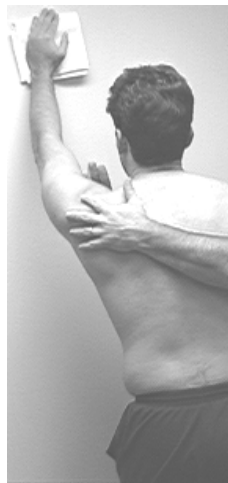
Impairment: Limited and Painful Shoulder Elevation



Shoulder Elevation MWM

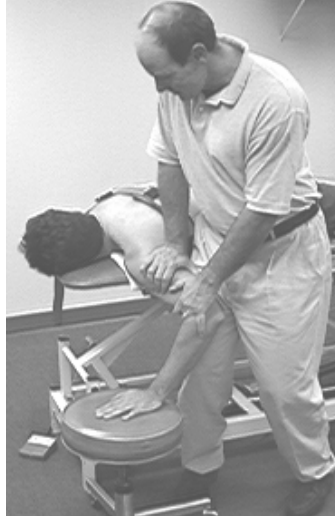- Cues:
- Position patient seated at the end of a raised treatment table
 - Stand to the side of the uninvolved shoulder
 - Stabilize scapula with one hand
 - Glide the humeral head posteriorly - parallel to the glenoid treatment plane
 - Sustain the glide as the patient actively elevates his humerus
 - Alter the amplitude and direction of the glide to achieve painfree active elevation
 - Repeat several times (sets of 10)
 - Progress the re-education with 1) lifting a weight during the MWM, or 2) overpressure at end of available active range – one option is illustrated below

The following reference provides additional information regarding this procedure:
Brian Mulligan MNZSP, DipMT: Manual Therapy, p. 88-91, 1995



Shoulder Elevation MWM
(with overpressure)

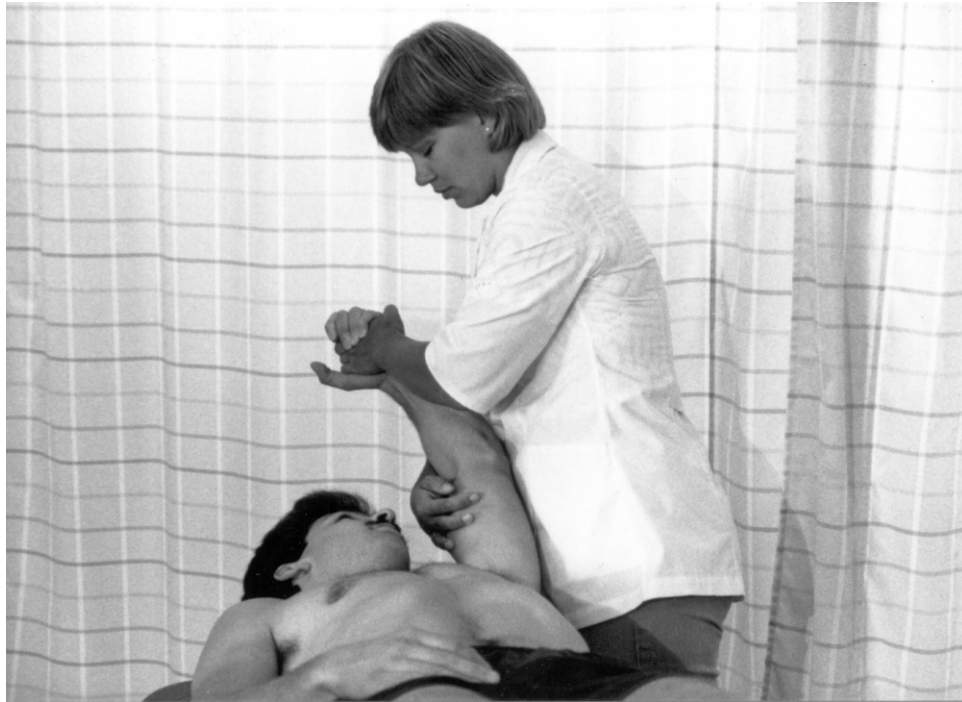Impairment: Limited Shoulder Elevation
Limited Glenohumeral External Rotation
Limited Humeral Anterior Glide



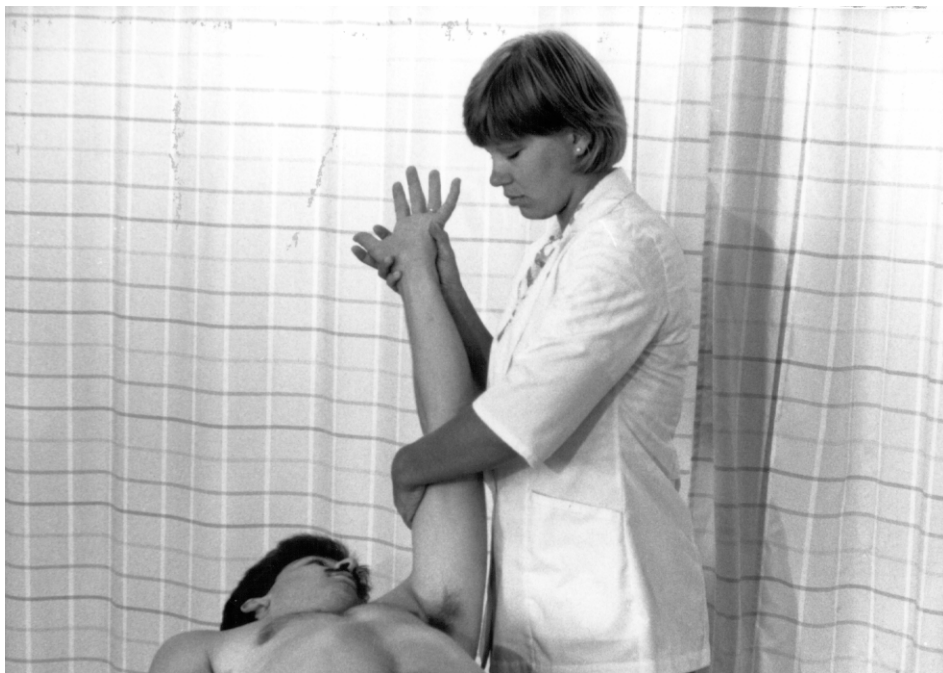Humeral Anterior Glide

Cues: Position the patient prone with the involved humerus off the side of the table – place a towel pad under the coracoid process and clavicle
A strap can be used to assist in stabilizing the scapula (especially when adding combined movements)
Hug the distal humerus into your thigh with one hand
Apply an anterior glide to the proximal humerus with the other hand
Use a soft flat hand
Generate the anterior glide with a trunk lean or slight bend of the knees
Consider adding combined movements of humeral distraction, abduction, horizontal abduction, or external rotation prior to the anterior glide (an adjustable, rolling stool can be used to provide the external rotation)

The following reference provides additional information regarding this procedure:
Freddy Kaltenborn PT: Manual Mobilization of the Extremity Joints, p. 112, 1989



Ext/Add/IR Contract-Relax



FLEX/ABD/ER facilitation