

Shoulder Movement Coordination Deficits

ICD-9-CM codes: 840.2 Shoulder ligament sprain
 840.0 Acromioclavicular joint sprain

ICF codes: Activities and Participation Domain codes:

d4305 Putting down objects (Using hands, arms or other parts of the body to place an object down on a surface or place, such as when lowering a container of water to the ground.)

d4451 Pushing (Using fingers, hands and arms to move something from oneself, or to move it from place to place, such as when pushing an animal away.)

d4452 Reaching (Using the hands and arms to extend outwards and touch and grasp something, such as when reaching across a table or desk for a book.)

d4300 Throwing (Using fingers, hands and arms to lift something and propel it with some force through the air, such as when tossing a ball.)

d4550 Crawling (Moving the whole body in a prone position from one place to another on hands, or hands and arms, and knees.)

d4551 Climbing (Moving the whole body upwards or downwards, over surfaces of objects, such as climbing steps, rocks, ladders of stairs, curbs or other objects.)

Body Structure code: **s7203** Ligaments and fasciae of shoulder region

Body Functions code: **b7601** Control of complex voluntary movements

Common Historical Findings

Glenohumeral ligaments and fasciae involvement:

Shoulder pain during activity - aching afterwards

Recurrent subluxations or dislocations with certain movements, positions, and activities

Apprehension

Acromioclavicular ligaments and fasciae involvement:

Trauma--a fall on the tip of the shoulder or a fall onto an outstretched arm

Pain with reaching across body, with overhead activities and with weight bearing on elbows or sleeping on the injured shoulder

Common Impairment Findings - Related to the Reported Activity Limitation or Participation Restrictions:

Glenohumeral ligaments and fasciae involvement:

Excessive glenohumeral accessory motion

Apprehension at end range elevation, horizontal abduction, and external rotation (if anterior instability)

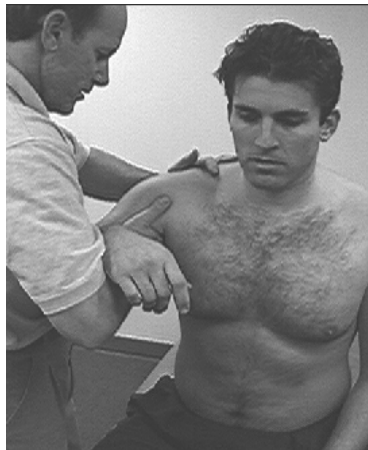
Acromioclavicular ligaments and fasciae involvement:

If Grade II or III sprain - palpable and observable displacement between the clavicular and acromial articular surfaces

Pain with accessory movement tests

Pain with palpation/provocation of acromioclavicular ligament

Physical Examination Procedures:



Glenohumeral Accessory Movement Test
Humeral Posterior Glide

Performance Cues:

Patient sits on end of table

Ensure “loose packed position”

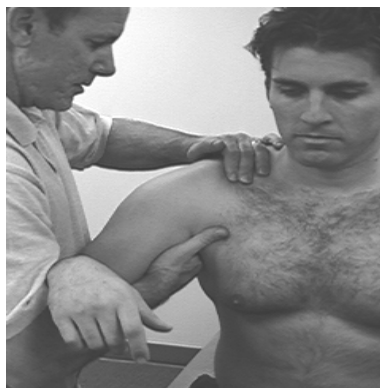
Do not elevate scapula

Allow the patient’s wrist to rest on your elbow

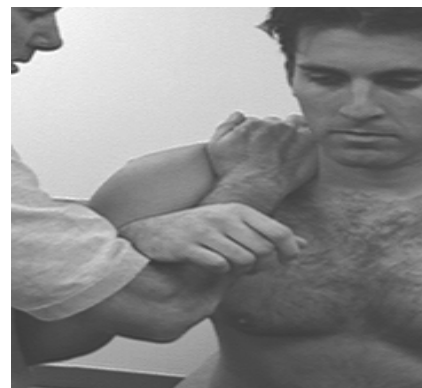
Stabilize spine of scapula with palm

Glide humerus (and thus, humeral head) posteriolaterally - in a direction parallel to the plane of the glenoid fossa

OK to use weight shift of thorax to produce glide



Glenohumeral Accessory Movement Test
Humeral Anterior Glide



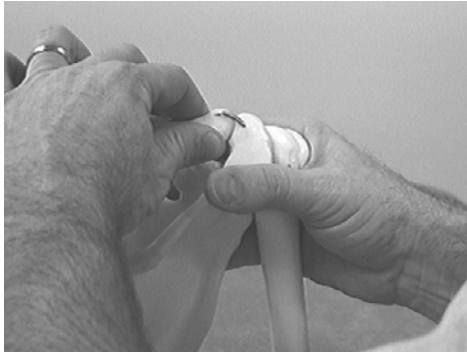Glenohumeral Accessory Movement Test
Humeral Anterior Glide

Performance Cues:

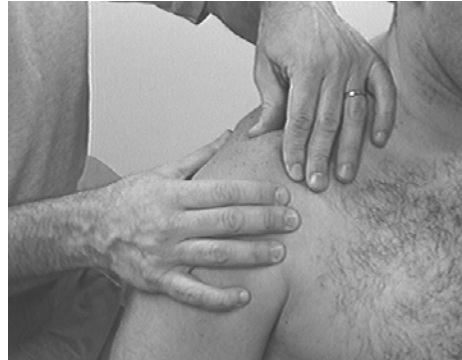Glide humeral head anteriomedially - in line with the treatment plane

Stabilize the clavicle with fingers or palm

Normal is an excursion that is less than one half of the width of the humeral head



A/C Joint Accessory Movement Test
Clavicular Anterior Glide



A/C Joint Accessory Movement Test
Clavicular Posterior Glide

Performance Cues:

Stand behind patient

Stabilize posteriorly via the spine of the scapula with you thumb and anteriorly via the glenoid fossa (hugging the humeral head into the fossa)

Grab the distal portion of the clavicle (it is OK to be somewhat medial to the A/C joint line - which may be tender), glide the clavicle anteriorly and posteriorly

Determine the amount of accessory motion and the patient's response to this movement provocation

Shoulder Stability Deficits: Description, Etiology, Stages, and Intervention Strategies

The below description is consistent with descriptions of clinical patterns associated with the vernacular term
“Glenohumeral Instability”

Description: This condition is the excessive mobility in the glenohumeral joint in one direction or more, where the humeral head slips out of the glenoid cavity or the patient feels that it is about to dislocate.

Etiology: The cause of glenohumeral instability could be due to traumatic or atraumatic (e.g., idiopathic glenohumeral ligament laxity or RA) causes that lead to dislocation of shoulder. The coracohumeral ligament is the primary restraint to inferior translation in adduction. The middle glenohumeral ligament is the primary restraint to anterior instability at 45° of abduction. The inferior glenohumeral ligament is the primary restraint to anterior instability from 45-90° of abduction and secondary to posterior instability. The superior ligament prevents inferior dislocation and stabilizes the shoulder during dependent positions. Instabilities are labeled anterior, posterior, inferior, and superior depending on the direction of laxity. In addition,

dynamic stability is provided by the muscular action of the supraspinatus, infraspinatus, subscapularis, and deltoid muscles along with the tendon of the longhead of the biceps.

Classification of Glenohumeral Instability is derived from four factors:

1. Frequency (acute, recurrent, chronic)
2. Causes (traumatic, atraumatic including voluntary, repeated micro trauma)
3. Direction (anterior, posterior, inferior, multidirectional)
4. Degree (subluxation, dislocation)

Acute Stage / Severe Condition: Physical Examinations Findings (Key Impairments)

ICF Body Functions code: b7601.3 SEVERE impairment of motor control/coordination of complex voluntary movements

- Patients with a recent ligament injury typically try to support the arm with opposite extremity and avoid using the injured arm
- Active shoulder movements are restricted and painful
- Passive and accessory movement testing reveals hypermobility of the glenohumeral joint

Note: The direction of laxity typically corresponds to the label given to the instability (e.g., excessive anterior glide corresponds with an anterior instability)

- Positive apprehension (Crank) test
- Supraspinatus and infraspinatus weakness is common
- Palpatory abnormalities may be present (e.g., with an anterior instability the humeral head may palpable anteriorly and shows a hollow beneath the acromion posteriorly.
- Axillary nerve injury is most commonly associated with an anterior shoulder dislocation leading to altered sensation in an area of the lateral shoulder

Sub Acute Stage / Moderate Condition: Physical Examinations Findings (Key Impairments)

ICF Body Functions code: b7601.2 MODERATE impairment of motor control/coordination of complex voluntary movements

As above with the following differences:

- Weakness is common to the dynamic stabilizers such as scapular upward rotators (trapezius, serratus anterior, rhomboids, and levator scapulae), and rotator cuff musculature (supraspinatus, infraspinatus, teres minor, and subscapularis) with contractions at end range of movement
- Now (when less acute) examine patient for co-existing upper quadrant impairments, such as upper thoracic and cervical pathologies, disorders of the acromioclavicular and sternoclavicular joints, muscle flexibility deficits such as tight pectoralis minor, pectoralis major, and/or serratus anterior and muscle strength deficits especially of the rotator cuff muscles and scapular upward rotators

Settled Stage / Mild Condition: Physical Examinations Findings (Key Impairments)

ICF Body Functions code: b7601.1 MILD impairment of motor control/coordination of complex voluntary movements

As above with the following differences:

- Shoulder symptoms are reproduced with repeated movements at end range

Intervention Approaches / Strategies

Acute Stage / Severe Condition:

Goals: Prevent further tissue damage

Re-establish non-painful mid-range mobility and avoid unstable positions with the involved shoulder

Retard muscle atrophy

Decrease pain and inflammation

- Physical Agents
 - Ice pack or ice massage
 - Electrical stimulation
- External Devices (Taping/Splinting/Orthotics)
 - Application of a shoulder sling may reduce pain, protect the joint from further injury and prevent excessive muscle guarding following a glenohumeral ligament injury
- Therapeutic Exercises
 - Pendulum and wand exercises in painfree, mid ranges
 - Isometric rotator cuff exercises in painfree, mid ranges
- Re-injury Prevention Instruction:
 - Temporarily limit abduction, flexion, lateral rotation and overhead activities or behind back activities that aggravate patient's symptoms.

Sub Acute Stage / Moderate Condition

Goals: As above

Regain and improve muscular strength and endurance

Regain and improve proprioception and neuromuscular control

- Therapeutic Exercises
 - Strengthening exercises for the dynamic stabilizers such as rotator cuff and scapular muscles in order to increase stability with pain free active movements at mid as well as end ranges
 - Upper body endurance can improved through use of mid range aerobic exercises such as rowing machines or upper body ergometers
- External Devices (Taping/Splinting/Orthotics)

Taping procedures may be used to 1) assist stabilization, 2) aid proprioception, and 3) promote scapular alignment

- Neuromuscular reeducation
Proprioceptive neuromuscular facilitation (PNF) patterns be used to facilitate neutral thoracic cage position, scapular posture, and shoulder proprioception
Closed chain shoulder stabilization exercises can be used to facilitate co-ordination with rest of the shoulder girdle
- Ergonomic Instruction
Promote efficient, pain free, motor control of the trunk, scapulae and arm with overhead activities
Modify activities to prevent repetitive strains or re-injury

Settled Stage / Mild Condition

Goals: As above

Increase power (Reaching 90% strength in the injured shoulder)
Progress activity tolerance and endurance
Increase neuromuscular control
Prepare individual for functional activities
Normalize upper quadrant posture, muscle flexibility, and muscle strength
Pain free AROM with increased stability with repeated active movements at end range

- Approaches / Strategies listed above
- Therapeutic Exercises
Stretching exercises for muscles that may have flexibility deficits, such pectoralis major, pectoralis minor, and latissimus dorsi
Strengthening exercises as above with using increased resistance
Utilitize muscular endurance exercises to maximize muscle performance of the relevant trunk, scapulae, shoulder girdle muscles required to perform the desired occupational or recreational activities
- Manual Therapy
Soft tissue mobilization for myofascia that may exhibit flexibility deficits, such pectoralis major, pectoralis minor, and latissimus dorsi
- Neuromuscular Reeducation
PNF techniques to increase shoulder control and stability with repeated movements at the end range

Intervention for High Performance / High Demand Functioning in Workers or Athletes

Goal: Return to desired occupational or leisure time activities

- Approaches / Strategies listed above

Selected References

Rockwood C., Masten III F., Fredrick A, The Shoulder 2nd ed. WBSaunders:Philadelphia, 1998.

Donatelli R., Physical Therapy of the Shoulder 3^{ed} ed. Churchill Livingstone, London. 1997.

Iannotti J, Williams G., Disorders of the Shoulder Diagnosis and Management, Lippincott: Philadelphia, 1999.

Kessel L., Clinical Disorders of the Shoulder, Churchill Livingstone, London. 1982.

Kibler WB, McMullen J, Uhl T: Shoulder rehabilitation strategies, guidelines, and practice. *Orthopedic Clinics of North America* 2001;32:527-538.

Rubin BD, Kibler WB: Fundamental principles of shoulder rehabilitation: Conservative to postoperative management. *J Arthroscopic Related Surgery* 2002:Suppl 2;18: 29-39.

Burkhead WZ, Rockwood CA: Treatment of instability of the shoulder with an exercise program. *J Bone Joint Surg.* 1992; 74-A: 890-896.

Kibler WB: The role of the scapula in athletic shoulder function. *Am J Sports Med* 1998;26:325-37.

Jobe Fw, Bradley JP: The diagnosis and nonoperative treatment of shoulder injuries in athletes. *Clinics in Sports Medicine* 1989 Jul; 8 (3): 419-437.

Dines DM, Levinson M: The conservative management of the unstable shoulder including rehabilitation. *Clinics in Sports Medicine* 1995;14:797-814.

Moseley JB, Jobe FW, Pink M, Perry J: EMG analysis of the scapular muscles during a shoulder rehabilitation program. *Am J Sports Med* 1992;20:128-134.

NevasierRJ, Nevasier TJ, Nevasier JS: Anterior dislocation of the shoulder and rotator cuff rupture. *Clinical Orthopaedic and Related Research* 1993; 291:103-106.

Hovellius L et al.: Recurrences after initial dislocation of the shoulder. *J Bone Joint Surg.* 1983;65A: 343-348.

Gamulin A, Pizzolato G, Stern R: Anterior shoulder instability: histomorphometric study of the subscapularis and deltoid muscles. *Clinical Orthopaedics* 2002;398:121-126.

Tibone JF, Lee TQ, Csintalan RP, Dettling J: Quantitative assessment of glenohumeral translation. *Clinical Orthopaedics* 2002;400: 93-97.

Shoulder Stability Deficits: Description, Etiology, Stages, and Intervention Strategies

The below description is consistent with descriptions of clinical patterns associated with the vernacular term
“**Acromioclavicular Instability**”

Description: Disruption of the ligamentous integrity of the acromioclavicular (also called A/C) joint. The acromioclavicular ligament may be damaged with excessive posteriorly directed translatory or rotatory force. The coracoclavicular ligaments (conoid and trapezoid) may be damaged with excessive superiorly or anteriorly directed forces.

Etiology: The cause of this injury is generally a traumatic incident such as a fall directly on the shoulder with the arm adducted or a fall on an outstretched hand.

Acute Stage / Severe Condition: Physical Examinations Findings (Key Impairments)

ICF Body Functions codes: **b7150.3** SEVERE impairments of stability of a single joint

- Protective posturing (e.g., cradling the arm and stabilizing it against the body)
- Variable elevation of the distal clavicle relative to the acromion
- Pain limited active shoulder flexion
- Pain with reaching across the body (horizontal abduction)
- Weak and painful with resisted shoulder flexion and shoulder abduction
- Tenderness to palpation over the acromioclavicular joint
- Symptoms reproduced with palpation or provocation of the A/C ligament
- Localized swelling around the joint
- Positive A/C compression or shear tests

Sub Acute / Moderate Condition: Physical Examinations Findings (Key Impairments)

ICF Body Functions codes: **b7150.3** MODERATE impairments of stability of a single joint

As above with the following differences:

- Pain with overhead activities
- Resisted shoulder flexion and abduction are now strong and painful

Settled Stage / Mild Condition: Physical Examinations Findings (Key Impairments)

ICF Body Functions codes: **b7150.3** MILD impairments of stability of a single joint

As above with the following differences:

- Resisted tests are now strong and painful only with repeated shoulder flexion and abduction
- Pain with repetitive activities of the shoulder especially at end range
- Pain with sustained end ranges stresses to the A/C, such as with prone-on-elbows positions

Intervention Approaches / Strategies

Acute Stage / Severe Condition

Goals: Avoid movements that increase inflammatory reactions
Decrease pain with daily activities

- Physical Agents
Ice
- External Devices (Taping/Splinting/Orthotics)
Taping may be used to assist in stabilization and to reduce pain
A sling may be used – especially if splint immobilization aids pain relief and limits aggravation of the injury
Type II A/C sprains may benefit from a Kenny- Howard splint
- Therapeutic Exercises
Active or passive shoulder abduction to 90 degrees and external rotation to 30 degrees are initiated at 2 weeks if no internal fixation has been used
Sub-maximal isometric exercises to maintain scapular and glenohumeral strength
- Re-injury Prevention Instruction
Temporarily limit end range ROM stretches, avoid vigorous work, avoid overhead activities

Sub Acute Stage / Moderate Condition

Goals: Prevent re-injury of the AC joint
Restore full pain-free active and passive range of motion of the shoulder girdle
Restore strength of the muscles around scapula and glenohumeral joint

- Therapeutic Exercises
Progress mobility exercises to regain full pain free range of motion
Progress strengthening exercises (e.g., Rotator cuff strengthening, closed chain exercises, progressive resistive exercises below 90 degree of flexion)
- Manual Therapy
Joint mobilization of glenohumeral joint to prevent restrictions

Settled Stage / Mild Condition

Goals: As above

- Approaches / Strategies listed above

- Re-injury Prevention Instruction
Progress activities to tolerance

Intervention for High Performance / High Demand Functioning in Workers and Athletes

Goal: Return to desired occupational or sport activities

- Therapeutic Exercises
Progress exercises focusing on job/sport specific training program based on individual needs of patient.

Selected References

Fukuda K, Craig KE, Kai-nan AN, Cofield RH Chao EYS. Biomechanical study of the ligamentous system of the acromioclavicular joint. *J Bone Joint Surg.* 1986; 68A:434-9.

Urist MR, Complete dislocation of the acromioclavicular joint: the nature of the traumatic lesion and effective methods of treatment with an analysis of 41 cases. *J Bone Joint Surg.* 1946;28:813-37.

Donatelli R, Wooden MJ. *Orthopedic Physical Therapy.* 2nd ed. 1994. Churchill Livingstone Inc.

Hulstyn MJ, Fadale PD. Shoulder Injuries in the athlete. *Clinical Sports Medicine.* 1997;16:663-679.

Dias JJ, Gregg PJ. Acromioclavicular joint injuries in sport. *Sports Medicine.* 1991;11: 125-32.

Bannister GC, Wallace WA, Stableforth PG, Hutson MA. The management of acute acromioclavicular dislocation. *J Bone Joint Surg.* 1989;71B:848-50.

Larsen E, Bierg-Nielsen A, Christensen P. Conservative or surgical treatment of acromioclavicular dislocation. *J Bone Joint Surg.* 1986;68(4):552-5.

Lemos MJ. The evaluation and treatment of the injured acromioclavicular joint in athletes. *Am J Sports Medicine.* 1998;26:137-44.

Turnbull JR. Acromioclavicular joint disorders. *Med Sci Sports Exercise.* 1998;30(4 suppl.):526-32.

Shamus JL, Shamus EC. A taping technique for the treatment of acromioclavicular joint sprains: a case study. *J Orthop Sports Phys Ther.* 1997;25:390-4.

Kisner C, Colby LA. *Therapeutic Exercises Foundations and Techniques.* Third Edition. 1996 F.A. Davis Company. Philadelphia, PA.