



PATIENT'S NAME: New, Patient
REFERRED BY: Dr. Example, DC
DATE OF FILMS: 12/21/2011
DOB: 0/00/0000

AGE:
D.O.S.

'Objective Spinal Motion Unit Assessment through AMA Precision Compliant Procedures'

Computer Aided Radiographic Mensuration Analysis

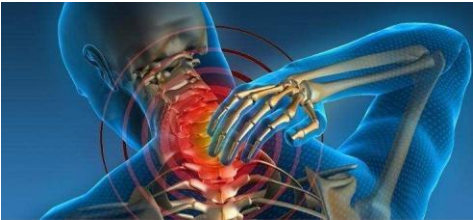This is a specialty radiology consultation that will provide the referring physician with radiologic analysis necessary to help determine the ligamentous and alignment factors of the spine for a more accurate diagnosis and a more precise treatment plan. This specialty report will also allow providers to rule in or rule out plain film impairment imaging factors according to AMA Guides (Guides to the Evaluation of Permanent Impairment, 5th Edition. Cocchiarella L and Andersson GBJ. AMA Press 2001). This separate and distinct analysis and report is performed in addition to the routine Plain Film professional interpretation report that was generated and reported separately. The following findings should be clinically correlated:

Lateral Cervical Spine: There are abnormal Lateral Baselines on neutral lateral x-ray. Interruptions of the George's Line at C2/C3, C3/C4 are indicative of ligamentous instability or sub failure. Jackson's angle demonstrates hypolorðosis and there appears to be abnormal stress lines associated with this finding.

Cervical Motion Study: There are abnormal Lateral Baselines. Jackson's angle appears to be compromised and indicates a possible focus of a fixation. The angular motion segment integrity is ratable at C3. The translation motion segment integrity is below ratable threshold.

IMPRESSIONS :

1. Abnormal straightening of the cervical spine.
2. Interruptions of the George's Line at C2/C3, C3/C4 are indicative of ligamentous instability or sub failure.
3. Ligamentous instability is indicated in the cervical spine with the measurements in this report. All findings must be clinically correlated to the doctor's clinical findings.
4. Cervical motion study (C1-C7) indicates Angular Motion Segment Integrity change at C3. The impairment of the cervical region is due to ratable Loss of Motion Segment Integrity and is ratable at 25% for cervical spine (AMA Guides, Fifth Edition, Errata). This patient's digital analysis reveals Loss of Motion Integrity at C3 = 11.81° yielding an impairment estimate based on plain film forensics at 25%.
5. Motion Segment Integrity, Translational variation is abnormal at C3 and C4. This patient's digital analysis reveals and C3 = 1.79 mm Posterior and C4 = 2.00 mm Posterior.



Russell G. Gelormini, D.O. Board Certified Radiologist

Signature on File, Electronically Signed

CERVICAL NOTES: *Measurements over 1mm Translation and / or over 7° Angular Variation are considered to be clinically significant and in excess of normal flexibility of the cervical spine. (SPINE 2001, February; 26(3): (256-261), Lin, Tsai, Chu and Chang.

**Abnormal measurements of more than 11° Angular Variation and / or greater than or equal to 3.5mm Translation (Loss of Motion Segment Integrity) by definition constitutes ligament damage which results in instability and calculates a whole person impairment of 25% to 28%. (Guides to the Evaluation of Permanent Impairment, Fifth Edition, 2000.) DRE Category IV.

***Lateral shift of Atlas on Axis greater than 1.7mm is considered subluxation and associated with poor prognosis for whiplash injury.

Krakenes J, Kaale BR, Moen G, Nordli H, Gilhus NE, Rorvik J. MRI assessment of the alar ligaments in the late stage of whiplash injury- structural abnormalities and observer agreement. Neuroradiology 2002 Jul;44(7):617-24.

SKWI

800 Wisconsin St. Bldg: D2, Suite 102, Mail Box 50, Eau Claire WI 54703

New Patient 12/21/2011			
LATERAL FLEXION [C7-SKULL]			
	PATIENT	ESTABLISHED ABNORMAL	ESTABLISHED RATABLE THRESHOLD
C3	11.81	7 - 11°	11.00°
C4	3.93	7 - 11°	11.00°
C5	0.17	7 - 11°	11.00°
C6	0.17	7 - 11°	11.00°

Motion Segment Integrity, Angular

New Patient 12/21/2011			
LATERAL EXTENSION [C7-SKULL]			
	PATIENT	ESTABLISHED ABNORMAL	ESTABLISHED RATABLE THRESHOLD
C3	11.81	7 - 11°	11.00°
C4	3.93	7 - 11°	11.00°
C5	0.17	7 - 11°	11.00°
C6	0.17	7 - 11°	11.00°

Motion Segment Integrity, Angular

A motion segment of the spine is defined as two adjacent vertebrae, an intercalated disk, and the vertebral facet joint. Loss of of motion segment or structural integrity is defined as abnormal back-and forth motion (translation) or abnormal angular motion of a motion segment with respect to an adjacent motion segment. The angular loss of integrity is defined as a difference in the angular motion of two adjacent motion segments greater than 11 degrees at C2/C3, C3/C4, C4/C5/ C5/C6,C6/C7, T1/T2, T2/T3 , T3/T4, T4/T5, T5,T6, T6/T7, T7/T8, T8/T9, T9/T10, T10/T11, T11/T12 , greater than 15 degrees at L1/L2, L2/L3, L3/L4 and greater than 20 degrees at L4/L5 in response to flexion and extension. Loss of integrity of the lumbosacral joint is defined as an angular motion between S1/L5 that is greater than 25 degrees greater than motion at L4/L5 level at 20 degrees.

(Ref: Guides to the Evaluation of Permanent Impairment, Fifth Edition)

SKWI

800 Wisconsin St. Bldg: D2, Suite 102, Mail Box 50, Eau Claire WI 54703

New Patient 12/21/2011			
LATERAL FLEXION [C7-SKULL]			
	PATIENT (MM)	ESTABLISHED ABNORMAL (MM)	ESTABLISHED RATABLE THRESHOLD (MM)
C2	0.24 P	1 - 3.5	3.50
C3	1.79 P	1 - 3.5	3.50
C4	2.00 P	1 - 3.5	3.50
C5	0.56 P	1 - 3.5	3.50
C6	0.54 A	1 - 3.5	3.50

Motion Segment Integrity, Translational

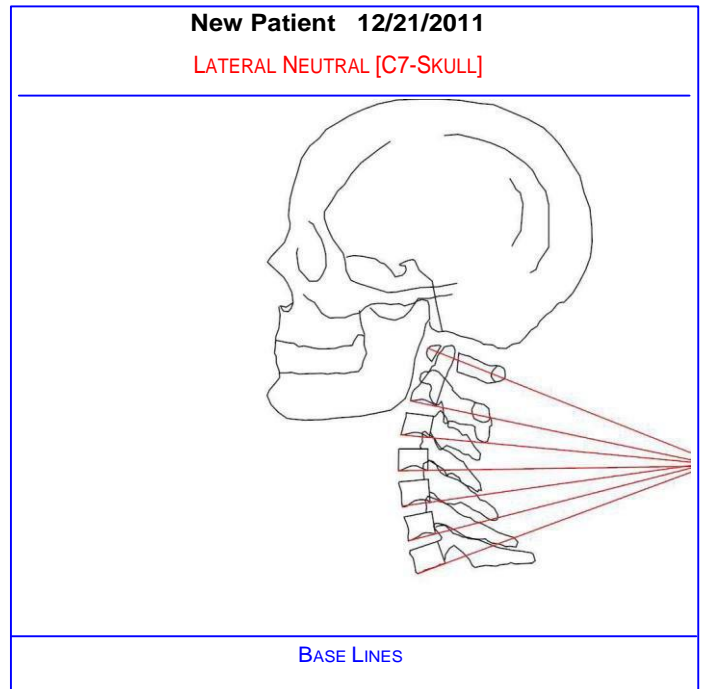
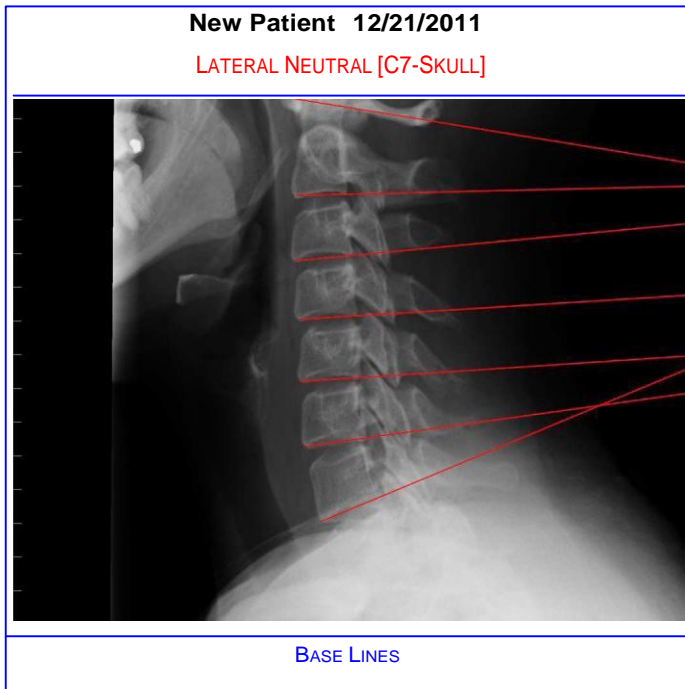
New Patient 12/21/2012			
LATERAL EXTENSION [C7-SKULL]			
	PATIENT (MM)	ESTABLISHED ABNORMAL (MM)	ESTABLISHED RATABLE THRESHOLD (MM)
C2	0.24 P	1 - 3.5	3.50
C3	1.79 P	1 - 3.5	3.50
C4	2.00 P	1 - 3.5	3.50
C5	0.56 P	1 - 3.5	3.50
C6	0.54 A	1 - 3.5	3.50

Motion Segment Integrity, Translational

Translational motion is measured by determining the anteroposterior motion of one vertebra over another. Loss of motion is defined by translational motion that is greater than 3.5 mm in the cervical spine, 2.5 mm in the thoracic spine and 4.5 mm in the lumbar spine. Using DRE Cervical Category IV, loss of motion segment integrity may be assessed as 25%-28% Impairment of the Whole Person. Using DRE Lumbar Category IV, loss of motion segment integrity may be assessed as 20%-23 % Impairment of the Whole Person.

SKWI

800 Wisconsin St. Bldg: D2, Suite 102, Mail Box 50, Eau Claire WI 54703



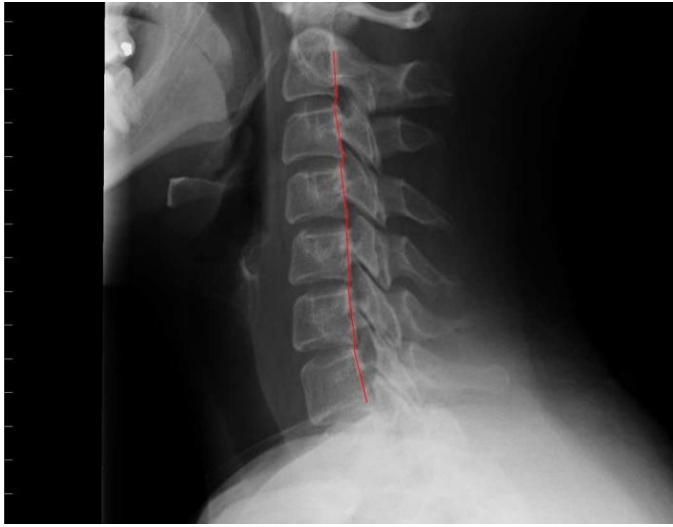
The lateral Base Lines are drawn from the inferior epiphyseal plates of each vertebra. The lines should converge on the posterior of the lateral spine view and converge at a central point. This is a qualitative analysis used to assist the physician in determining fixed flexion or fixed extension of vertebra (e). When a base line intersects with the next superior base line, this indicates fixed flexion of the inferior vertebra (e) while a base line intersecting with the next inferior vertebra indicates fixed extension of the superior vertebra. If not corrected this may leads to biomechanical dysfunction, which may assist with or lead to premature degenerative changes. (Wolf's Law)

SKWI

800 Wisconsin St. Bldg: D2, Suite 102, Mail Box 50, Eau Claire WI 54703

New Patient 12/21/2011

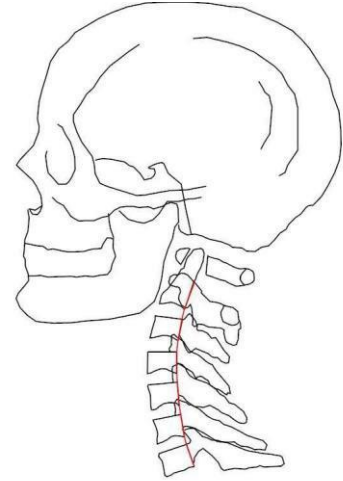
LATERAL NEUTRAL [C7-SKULL]



George's Line C2/C3 and C3/C4

New Patient 12/21/2011

LATERAL NEUTRAL [C7-SKULL]



George's Line

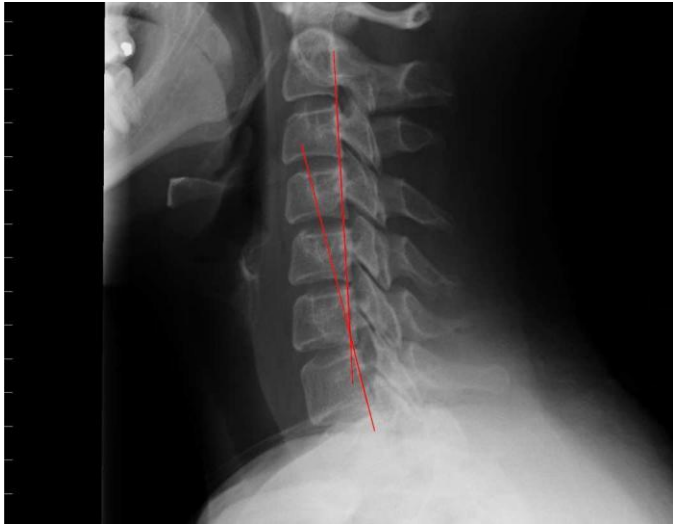
George's Line is also known as the posterior vertebral alignment line and the posterior body line. George's line is a measure of spinal ligament integrity of the posterior longitudinal ligament and vertebral body alignment. The key landmark is the alignment and integrity of one vertebra to each superior and inferior vertebra. The normal translation or laxity of each vertebral motor unit is 0.0 to 0.6 mm. Normally, there is a smooth vertical alignment of each posterior body corner. Interruption of a smooth curve is suggestive of ligament instability due to fracture, dislocation, trauma with ligamentous sub-failure or degenerative joint disease which can cause or aggravate spinal stenosis with resultant altered spinal biomechanics, and degenerative changes.

SKWI

800 Wisconsin St. Bldg: D2, Suite 102, Mail Box 50, Eau Claire WI 54703

New Patient 12/21/2011

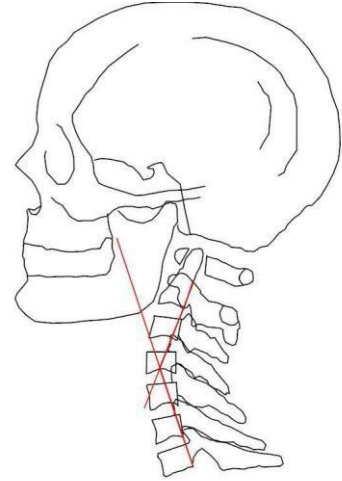
LATERAL NEUTRAL [C7-SKULL]



Jackson's Angle -10.93°

New Patient 12/21/11

LATERAL NEUTRAL [C7-SKULL]


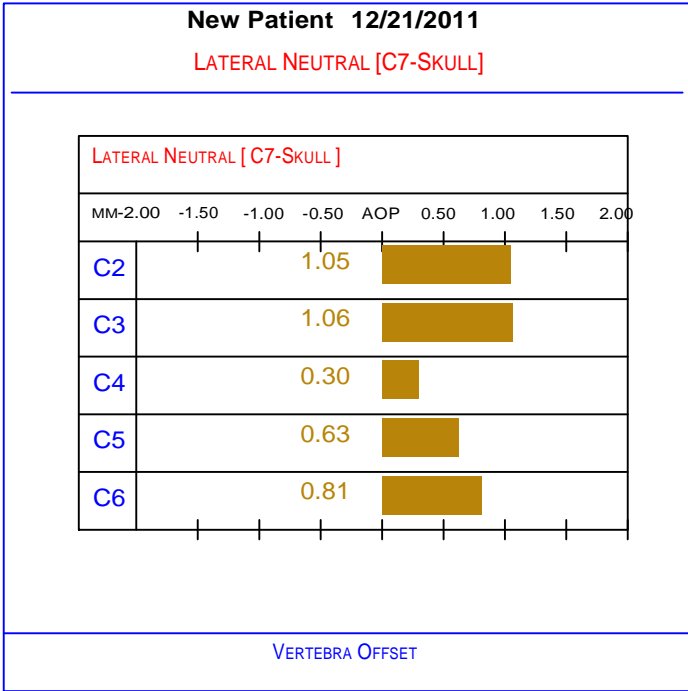


Jackson's Angle -39.91°

Ruth Jackson's Angle is also known as Cervical Stress Lines, which is measured by constructing lines of mensuration from the posterior bodies of C-2 and C-7. These lines will form an angle which ordinarily intersect at the C4-C5 disc interspace in the neutral and extension view and C5-C6 disc interspace in flexion. The intersection point represents the focus of stress when the cervical spine is placed in the respective position. Muscle spasms, joint fixation, and disc degeneration may alter the stress point.

SKWI

800 Wisconsin St. Bldg: D2, Suite 102, Mail Box 50, Eau Claire WI 54703

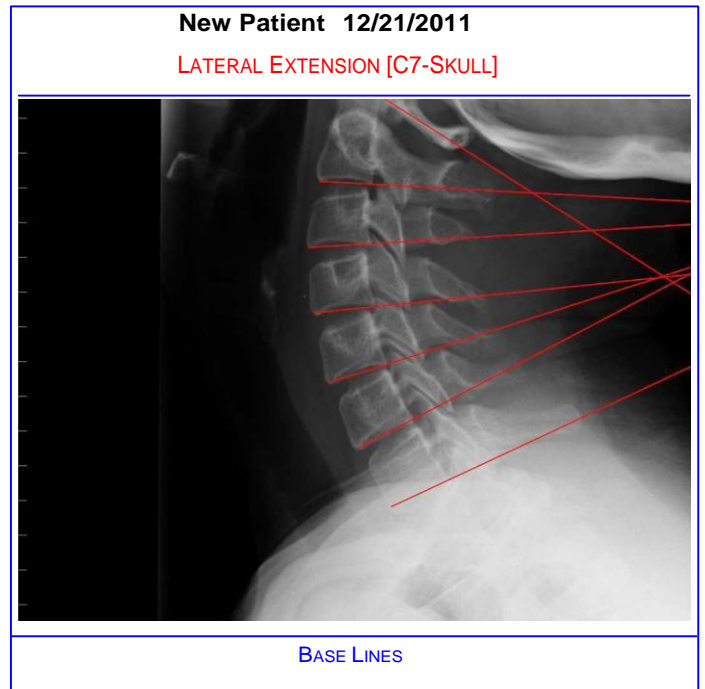
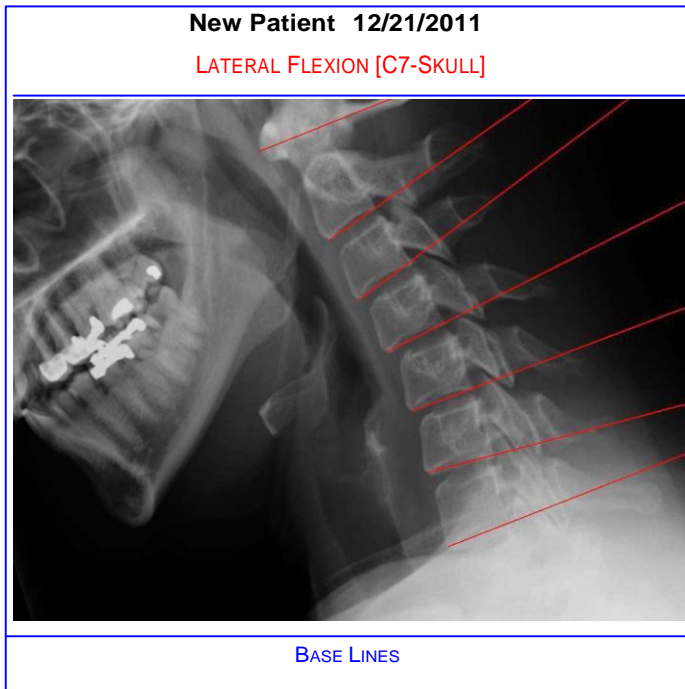


Lateral Flexion=Translatory Posterior displacement is measured from the posterior inferior corner of the body of the superior vertebra to the posterior superior corner of the inferior vertebra. Measurement of 1-3mm is considered to be a subluxation. A displacement of more than 3.5mm in the cervical spine and 4.5mm in the lumbar spine radiographs qualifies for alteration of motion segment integrity. Reference:

1. Guides to the Evaluation of Permanent Impairment, Fourth Edition, Errata.

SKWI

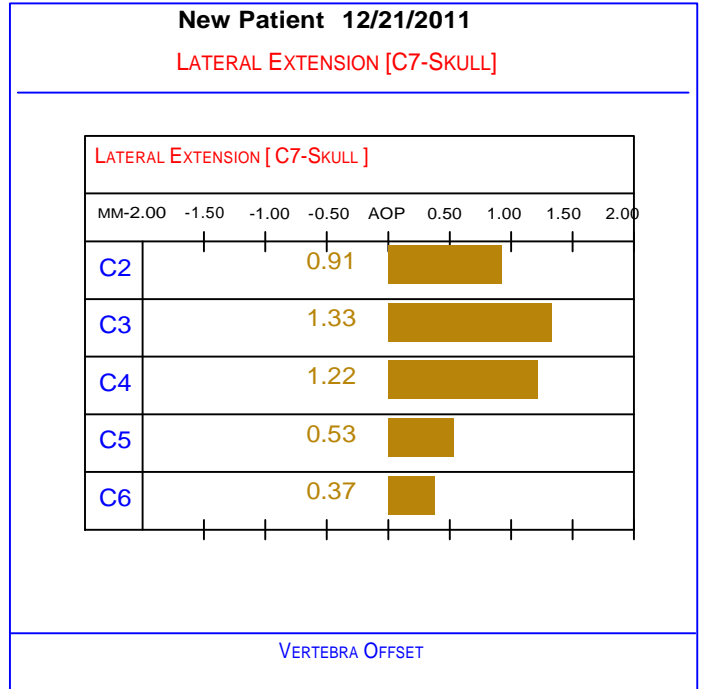
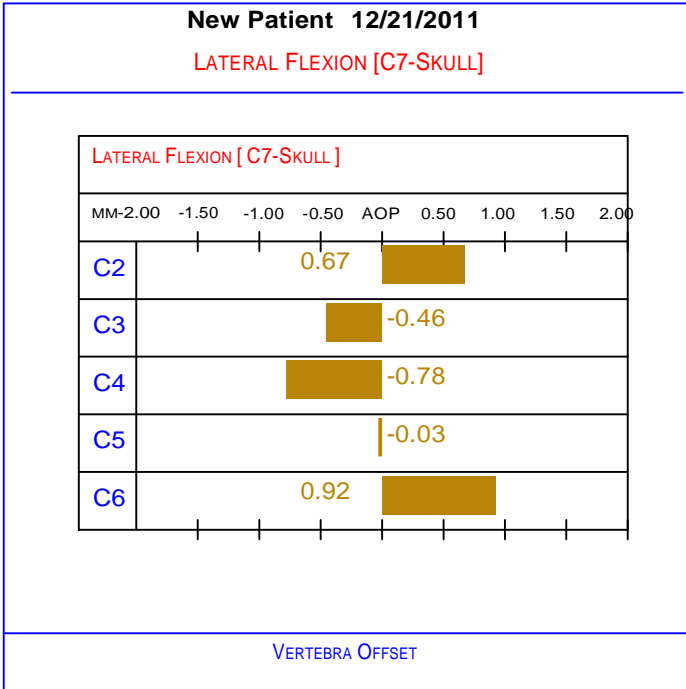
800 Wisconsin St. Bldg: D2, Suite 102, Mail Box 50, Eau Claire WI 54703



The lateral Base Lines are drawn from the inferior epiphyseal plates of each vertebra. The lines should converge on the posterior of the lateral spine view and converge at a central point. This is a qualitative analysis used to assist the physician in determining fixed flexion or fixed extension of vertebra (e). When a base line intersects with the next superior base line, this indicates fixed flexion of the inferior vertebra (e) while a base line intersecting with the next inferior vertebra indicates fixed extension of the superior vertebra. If not corrected this may leads to biomechanical dysfunction, which may assist with or lead to premature degenerative changes. (Wolf's Law)

SKWI

800 Wisconsin St. Bldg: D2, Suite 102, Mail Box 50, Eau Claire WI 54703



Lateral Flexion=Translatory Posterior displacement is measured from the posterior inferior corner of the body of the superior vertebra to the posterior superior corner of the inferior vertebra. Measurement of 1-3mm is considered to be a subluxation. A displacement of more than 3.5mm in the cervical spine and 4.5mm in the lumbar spine radiographs qualifies for alteration of motion segment integrity. Reference:

1. Guides to the Evaluation of Permanent Impairment, Fourth Edition, Errata.

Russell G. Gelormini, D.O. Board Certified Radiologist

Signature on File, Electronically Signed